




FOXG1 variants can be associated with milder phenotypes than congenital Rett syndrome with unassisted walking and language development

Benoit Mazel^{1,2}  | Julian Delanne^{1,3} | Aurore Garde^{1,2}  | Caroline Racine^{1,2} | Ange-Line Bruel^{2,4} | Yannis Duffourd^{2,4} | Diego Lopergolo⁵ | Filippo Maria Santorelli⁵ | Viviana Marchi⁶ | Anna Maria Pinto⁷ | Maria Antonietta Mencarelli⁷ | Roberto Canitano⁸ | Floriana Valentino⁹ | Filomena Tiziana Papa⁹ | Chiara Fallerini^{9,10} | Francesca Mari^{7,9} | Alessandra Renieri^{7,9,10} | Arnold Munnich¹¹ | Tanguy Niclass¹² | Gwenaël Le Guyader¹² | Christel Thauvin-Robinet^{1,2,3,4} | Christophe Philippe^{2,4} | Laurence Faivre^{1,2} 

¹Centre de Référence Anomalies du Développement et Syndromes Malformatifs, Centre de Génétique, FHU TRANSLAD - CHU Dijon Bourgogne, Dijon, France

²Inserm UMR1231 GAD, Génétique des Anomalies du Développement, Université de Bourgogne, Dijon, France

³Centre de référence Déficiences Intellectuelles de Causes Rares, CHU Dijon Bourgogne, Dijon, France

⁴Laboratoire de Génomique Médicale, Unité Fonctionnelle Innovation en diagnostic génomique, Unité fonctionnelle innovation en diagnostic génomique des maladies rares, CHU Dijon Bourgogne, Dijon, France

⁵Molecular Medicine for Neurodegenerative and Neuromuscular Diseases Unit, IRCCS Stella Maris Foundation, Pisa, Italy

⁶Department of Developmental Neuroscience, Stella Maris Scientific Institute, IRCCS Fondazione Stella Maris Foundation, Pisa, Italy

⁷Genetica Medica, Azienda Ospedaliera Universitaria Senese, Siena, Italy

⁸Division of Child and Adolescent Neuropsychiatry, University Hospital of Siena, Siena, Italy

⁹Medical Genetics Unit, University of Siena, Policlinico Le Scotte, Siena, Italy

¹⁰Department of Medical Biotechnologies, Med Biotech Hub and Competence Center, University of Siena, Siena, Italy

¹¹Service de Génétique Médicale et Clinique, Hôpital Necker Enfants Malades, Paris, France

¹²Service de Génétique Clinique, CHU de Poitiers, Poitiers, France

Correspondence

Laurence Faivre, Centre de Génétique, Hôpital d'Enfants, 14 rue Gaffarel, 21079 Dijon Cedex, France.

Email: laurence.faivre@chu-dijon.fr

Funding information

Dijon University Hospital; European Regional Development Fund; Ricerca Corrente 5X1000

Abstract

Since 2008, *FOXG1* haploinsufficiency has been linked to a severe neurodevelopmental phenotype resembling Rett syndrome but with earlier onset. Most patients are unable to sit, walk, or speak. For years, *FOXG1* sequencing was only prescribed in such severe cases, limiting insight into the full clinical spectrum associated with this gene. Next-generation sequencing (NGS) now enables unbiased diagnostics. Through the European Reference Network for Rare Malformation Syndromes, Intellectual and Other Neurodevelopmental Disorders, we gathered data from patients with heterozygous *FOXG1* variants presenting a mild phenotype, defined as able to speak and

This is an open access article under the terms of the [Creative Commons Attribution-NonCommercial-NoDerivs](https://creativecommons.org/licenses/by-nc-nd/4.0/) License, which permits use and distribution in any medium, provided the original work is properly cited, the use is non-commercial and no modifications or adaptations are made.

© 2024 The Authors. *American Journal of Medical Genetics Part B: Neuropsychiatric Genetics* published by Wiley Periodicals LLC.

walk independently. We also reviewed data from three previously reported patients meeting our criteria. We identified five new patients with pathogenic *FOXG1* missense variants, primarily in the forkhead domain, showing varying nonspecific intellectual disability and developmental delay. These features are not typical of congenital Rett syndrome and were rarely associated with microcephaly and epilepsy. Our findings are consistent with a previous genotype–phenotype analysis by Mitter et al. suggesting the delineation of five different *FOXG1* genotype groups. Milder phenotypes were associated with missense variants in the forkhead domain. This information may facilitate prognostic assessments in children carrying a *FOXG1* variant and improve the interpretation of new variants identified with genomic sequencing.

KEYWORDS

congenital Rett syndrome, *FOXG1* gene, *FOXG1* phenotype spectrum, mild phenotype

1 | INTRODUCTION

Forkhead box G1 (*FOXG1*) is part of the highly conserved forkhead box transcription factors superfamily. Mainly expressed in a variety of nervous system cell types and tissues, it has been shown that *FOXG1* plays a major role in brain development, including telencephalon specification and patterning, neuronal differentiation and survival maintenance of mature neurons, and retina, inner ear, and olfactory bulb development (Hettige & Ernst, 2019; Kumamoto & Hanashima, 2017; Toresson et al., 1998; Xuan et al., 1995).

FOXG1 haploinsufficiency is a rare cause of early-onset neurodevelopmental disorders known as “*FOXG1*-related syndrome” or “*FOXG1*-related encephalopathy”. First described in 2008, this syndrome is also known as congenital variant of Rett syndrome because it has phenotypic similarities with typical Rett syndrome linked to *MECP2* (methyl-CpG-binding protein 2) variants (Ariani et al., 2008). Typically, heterozygous pathogenic variants in *FOXG1* result in severe neurodevelopmental encephalopathy whose main clinical features include severe to profound intellectual disability (ID), psychomotor delay (inability to walk and to use hands purposefully, absence of speech), drug-resistant epilepsy, and morphological brain anomalies (Kortüm et al., 2011; Wong, Singh, et al., 2019; Wong, Wu, et al., 2019). Rett syndrome almost exclusively affects females and is characterized by a similar clinical presentation but with normal growth and development for the first 6–18 months of life, followed by a slowing of development and the loss of some acquired motor and speech skills. However, unlike typical Rett syndrome, the congenital variant is not X-linked, and most patients lack some characteristic clinical features and therefore do not meet all the diagnostic criteria for Rett syndrome (Collins & Neul, 2022).

Recently, a 3-year-old boy was referred to our genetics department for the mild psychomotor delay. Exome sequencing (ES) identified a heterozygous de novo missense variant in the *FOXG1* gene meeting the American College of Medical Genetics (ACMG) criteria for pathogenicity (PS2, PM1, PP3, PP5, and PM2). However, it was first classified as a variant of unknown significance because of

the mismatch between the mild phenotype and what is usually described with *FOXG1* variants. To reclassify the variant as likely pathogenic, a collegial exchange with international experts was required.

Although some attenuated forms of congenital Rett syndrome have been described in the literature (Khan & Kirmani, 2020; Méneret et al., 2012; Vegas et al., 2018), these cases remain rare. Currently, it may still be unclear to some physicians or biologists that *FOXG1* variants can be associated with phenotypes that are milder than congenital Rett syndrome. With this study, we aim to provide a short review and data from a small cohort of patients presenting with a mild form of *FOXG1* syndrome to help geneticists make an early diagnosis and improve the management of affected patients.

2 | METHODS

Through international data sharing (European Reference Network for Rare Malformation Syndromes, Intellectual and Other Neurodevelopmental Disorders [ERN-ITHACA] and collaborators from the AnDDI-Rares network [*Filière de Santé Anomalies du Développement avec ou sans Déficience intellectuelle de causes Rares*]), we gathered the phenotypic and genetic data for five unrelated probands carrying heterozygous pathogenic or likely pathogenic (P/LP) *FOXG1* variants with a mild presentation of *FOXG1* syndrome, defined as a patient who acquires speech and can walk independently.

Using PubMed, we also searched the National Center for Biotechnology Information database to identify studies reporting patients with *FOXG1* syndrome (case reports and prospective or retrospective cohorts). We reviewed the data from three previously described cases involving patients with a mild expression of this syndrome, according to our definition.

The procedures followed for genetic testing were in accordance with ethical standards, and appropriate informed consent was obtained from all individuals. Individuals underwent ES or multigene panel sequencing as part of their care. Variants were classified according to the ACMG guidelines (Richards et al., 2015).

TABLE 1 Phenotypic features of our cohort and the three reviewed cases identified in the literature with a mild presentation of FOXP1 syndrome.

Variant ^a	Patient 1 (France)	Patient 2 (France)	Patient 3 (Italy)	Patient 4 (France)	Patient 5 (Italy)	Philippe et al. (2010)	Mitter et al. (2018)	Jang et al. (2021)
DNA	c.713G>A	c.647C>T	c.708C>A	c.1178C>G	c.553A>G	c.1200C>G	c.1141delG	c.761A>C
Protein	p.(Cys238Tyr)	p.(Pro216Leu)	p.(Asn236Lys)	p.(Ser393Trp)	p.(Ser185Gly)	p.(Tyr400*)	p.(Ala381Profs*4)	p.(Tyr254Ser)
Demographics								
Sex	M	M	F	F	F	F	F	F
Age at last examination	6 years	9 years	39 years	12 years	2 years 5 months	10 years	17 years	5 years
Development								
ID/DD	Moderate	Moderate	Severe	Mild	Mild	Severe	Severe	Profound
Unassisted sitting at follow-up	+	+	+	+	+	+	+	+
Unassisted sitting age (months)	17	9	10	7	10	NA	11	13
Unassisted walking	+	+	+	+	+	+	+	+
Walking age (months)	26	17	18	13	21	30	132	24
Motor skills	Runs, jumps, ascends, and descends stairs by himself; plays football	Runs, ascends and descends stairs by himself, rides a bike with training wheels	Walks unassisted although with a wide base, holds and uses small objects (e.g., fork)	Walks autonomously	Walks autonomously	Walks autonomously	Walks autonomously	Walks autonomously
Speech at follow-up	+	+	+	+	+	+	+	+
Age at first words (months)	19	12	12	NA	18	NA	NA	35
Language skills	About 5 fluent words and 15 signs in sign language	Started learning to read and write	Primarily composed of words with a large vocabulary	Demonstrates correct verbal production, can read and write	Understands short sentences, produces about 10 words	Capable of saying a few words	Uses 10 spoken words	Communicates verbally
Regression	-	-	-	-	-	-	+	-

(Continues)

TABLE 1 (Continued)

	Patient 1 (France)	Patient 2 (France)	Patient 3 (Italy)	Patient 4 (France)	Patient 5 (Italy)	Philippe et al. (2010)	Mitter et al. (2018)	Jang et al. (2021)
Neurologic								
Epilepsy	-	-	+	-	-	-	+	-
Abnormal muscle tone	+	+	-	-	+	+	+	+
Spasticity	-	-	-	-	+	NA	+	-
Stereotypic movements	+	-	+	+	+	+	+	-
Brain MRI	Mild delayed myelination and mild ventriculomegaly	Normal	NA	Simplified gyration, some cystic dilatations, white matter T2 hypersignals, corpus callosum hypoplasia (third per)	Normal	Normal	Cortical anomalies	Slightly delayed myelination, mildly enlarged lateral ventricles, hypoplastic olfactory bulbs, mild thinning of the rostrum of the corpus callosum
Other								
Microcephaly	-	-	+	-	-	+	-	+
Scoliosis	-	-	-	-	-	-	-	NA

Abbreviations: DD, developmental delay; F, female; FOXG1, forkhead box G1; ID, intellectual disability; M, male; MRI, magnetic resonance imaging; NA, not available; per, percentile.

^a Variants are named according to NM_005249.5.

TABLE 2 Comparison between phenotypes in our cohort and the three cases identified in the literature, and the main features of congenital Rett syndrome in the cohort described by Mitter et al. (2018).

	Total of the cohort and the three reviewed cases (n and % or mean/median)		Congenital variant of Rett syndrome Mitter et al. (2018) Total cohort (n = 81) (% or mean/median)	Mitter et al. (2018) Forkhead domain missenses only, including in the conserved site 1 (n = 21) (n and % or mean/median)	
Age at last examination (months)	150/114		105/78	87.5/NA	
Development					
Intellectual disability/developmental delay	Variable		Variable	Variable	
Unassisted sitting at follow-up	8/8	100%	45%	15/17	88%
Unassisted sitting age (months)	11/10		28/18	NA	
Unassisted walking at follow-up	8/8	100%	15%	8/21	38%
Walking age (months)	35/22		53/45	NA	
Speech at follow-up	8/8	100%	21%	6/20	30%
Age at first words (months)	19/18		46/33	NA	
Regression	1/8	12.5%	18%	1/12	8%
Neurological features					
Epilepsy	2/8	25%	68%	11/21	52%
Abnormal muscle tone	6/8	75%	95%	NA	
Spasticity	2/7	29%	60%	6/15	40%
Stereotypic movements	6/8	75%	90%	13/15	87%
Other					
Microcephaly	3/8	38%	84%	13/18	72%
Scoliosis	0/8	0%	40%	4/12	33%
MRI features					
Normal	3/7	43%	NA	NA	
Corpus callosum anomalies	2/7	29%	67%	4/14	28.5%
Delayed myelination	2/7	29%	56%	3/10	30%
Cortical anomalies	2/7	29%	72%	8/12	67%
Ventriculomegaly	2/7	29%	NA	NA	

Abbreviations: MRI, magnetic resonance imaging; NA, not available.

3 | RESULTS

Patients in our cohort were recruited from five centers in France and Italy (detailed case reports in Supporting information). We also reviewed the clinical data of three patients described in the literature as having a mild presentation (Jang et al., 2021; Mitter et al., 2018; Philippe et al., 2010). The clinical characteristics of the cohort and a comparison with the results of Mitter et al., involving 83 patients with FOXP1 syndrome, are summarized in Tables 1 and 2.

All cases presented with nonspecific ID, ranging from mild to severe, and distinct from the profound ID exhibited in the congenital variant of Rett syndrome. They were able to walk unassisted even if they still presented coordination and praxis difficulties. Fine motor skills were affected in all patients. Similarly, speech development was delayed but present. However, some patients had poorly developed language, sometimes with only a few spoken words, but still appropriately used. Postnatal microcephaly was present in three cases and seizures were present in only two patients who both responded well to anti-epileptic medication. Brain imaging was normal or

revealed anomalies that were milder than those encountered in congenital Rett syndrome (Ariani et al., 2008; Mencarelli et al., 2010; Mitter et al., 2018). Some other clinical features typically found in congenital Rett syndrome, such as stereotypies (hands, head, and/or trunk), hypotonia, and impaired social interactions, were frequently observed in our cohort but were mostly less severe.

All patients in the cohort carried P/LP heterozygous missense FOXP1 variants, identified by ES in patients 1 and 4 and by multigene panel sequencing in patients 2, 3, and 5. Four variants were de novo, while inheritance has not been tested for the fifth. Four of the variants were located in the forkhead domain (FHD), including one in the conserved site 1 of the FHD (patient 5), and the last variant was located in the JARID1B-binding domain (JBD) (Figure 1). Patient 5 had one of the mildest phenotypes in the cohort. Among the five variants reported here, there are two novel variants that were previously not reported as pathogenic in the dbSNP (<https://www.ncbi.nlm.nih.gov/snp/>), ClinVar (<https://www.ncbi.nlm.nih.gov/clinvar/>), and gnomAD v3.1.2 (<https://gnomad.broadinstitute.org/>) databases [NM_005249.5: c.553A>G, p.(Ser185Gly) and c.647C>T, p.(Pro216Leu)]. The three

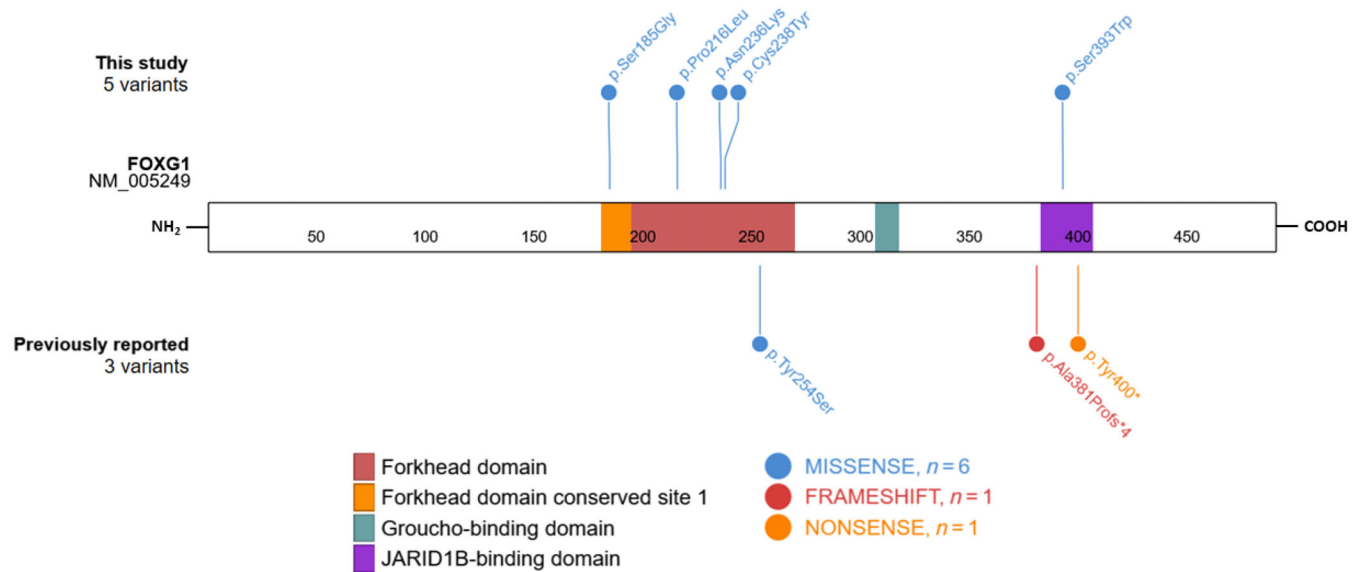


FIGURE 1 Schematic representation of the forkhead box G1 (FOGX1) protein and distribution of the pathogenic variants reported in our cohort and in other previously published studies with mild presentations.

remaining variants were already reported in ClinVar, but detailed clinical features were not available.

Variants previously reported in the literature and associated with a mild form of FOXG1 syndrome (Table 1) included one missense variant (p.Tyr254Ser) located in the FHD, one nonsense variant (p.Tyr400*) located in the JBD, and one frameshift variant (p.-Ala381Profs*4) located just upstream from the JBD and leading to a transcription disruption at the very beginning of the sequence coding for this domain. We can therefore define, among the eight variants, two types of variations: (1) missenses in the FHD and (2) premature stop codon with preserved FHD and Groucho-binding domain but with truncated or absent JBD.

We then compared our cohort to the general cohort gathered by Mitter et al., who described different groups of patients depending on the type and position of variants (missense versus frameshift and nonsense; N-terminal versus FHD except conserved site 1 versus conserved site 1 versus C-terminal). When we compared our cohort with the patients from Mitter et al. (2018) who tended to have the least severe clinical features, that is, those carrying missense variants in the FHD (including in the conserved site 1), our cohort exhibited much milder phenotypes (Table 2).

4 | DISCUSSION

Since *FOGX1* was first identified as being responsible for the congenital variant of Rett syndrome in 2008 by Ariani et al., most cases have been found to present with profound psychomotor disability (Allou et al., 2012; Bahi-Buisson et al., 2010; Cellini et al., 2016; Le Guen et al., 2011; Terrone et al., 2014; Van der Aa et al., 2011). For years, targeted sequencing of *FOGX1* was only prescribed in such severe cases. However, the improvement and wider use of

NGS has made it possible to highlight causal genetic anomalies in patients for whom no formal diagnosis could be made from clinical evidence, which has led to the observation of milder forms of FOXG1 syndrome.

With this study, we describe a new class of patients with FOXG1 syndrome that present a phenotype that is much milder than congenital Rett syndrome. We have defined this mild phenotype as patients walking unassisted and able to communicate verbally. Though rare, several previous studies have contributed to our knowledge of mild forms of FOXG1 syndrome (De Filippis et al., 2012; Kortüm et al., 2011; Mencarelli et al., 2010). In our cohort, phenotypes and variant distribution (located within the FHD and the C-terminal part of the protein) are consistent with the observations of Mitter et al., who, in 2018, described a large cohort of patients presenting with FOXG1 syndrome and highly variable phenotype expressivity. The authors focused on the genotype–phenotype relationship observed in their cohort and suggested the delineation of the *FOGX1* genotypes into five different groups. Milder phenotypes were associated with *FOGX1* missense variants in the FHD, and carriers of variants in the conserved site 1 presented with the mildest phenotype. However, some patients with a missense variant in the FHD (including in the conserved site 1) still exhibited a severe phenotype, including 62% who were unable to walk unassisted and 70% who did not acquire verbal speech. Frameshift and nonsense variants located in the FHD were responsible for a more severe phenotype: none of the patients acquired walking or speech, and these variants were associated with a higher rate of brain malformations. It is worth emphasizing that the single exon structure of *FOGX1* prevents abnormal mRNA containing premature stop codons from undergoing nonsense-mediated mRNA decay. Consequently, premature truncating variants in this gene most probably result in the production of truncated proteins. This mechanism likely contributes to the increased pathogenicity of nonsense

and frameshift variants before or affecting the FHD, as opposed to missense variants.

C-terminal truncating variants, on the other hand, were responsible for both mild and severe presentations. Frullanti et al. (2019) also noted, in their cohort of 26 patients, that *FOXG1* late truncating variants tended to result in a less severe phenotype than early truncating variants. This correlates with the review from Akol et al. (2022) in which truncating mutations in the N-terminal domain and the FHD seemingly caused more severe phenotypes than missenses and variants affecting the C-terminus. However, the authors also noted, based on the observations of Vegas et al. (2018), that some mutation hotspots were associated with highly variable features and severity, indicating a poor genotype–phenotype correlation. It is thus plausible that additional genetic and/or environmental factors modulate the clinical phenotypes observed in *FOXG1*-related disorders. Notably, the possibility that genetic alterations in other genes or regulatory sequences may contribute to the phenotype should be considered. This could be particularly relevant for patients who have undergone targeted sequencing of *FOXG1* or a panel of genes.

Conversely, many benign or likely benign missense variants located outside the functional domains, especially in the N-terminal part of the protein, are reported in the gnomAD and ClinVar databases, indicating regions with tolerance to missenses.

Finally, our definition of the mild form of *FOXG1* syndrome could have been refined, for instance regarding the number of spoken words, to reflect the variability of phenotypes encountered in this syndrome more precisely. Nevertheless, refining the definition would be challenging due to the rarity of mild forms and the fact that some patients are very young and future psychomotor progress cannot yet be established. For instance, we could not include the patient reported by Khan & Kirmani (2020), although considered by the authors as presenting a mild phenotype. The authors described a boy aged 4 years and 10 months carrying a de novo heterozygous *FOXG1* variant (p.Gln86Profs*35) and presenting with postnatal microcephaly and delayed developmental milestones, but he had a neurological phenotype that was considerably less severe than usual in patients with congenital Rett syndrome. At publication, the boy could not yet walk unassisted and remained nonverbal. This example highlights the difficulties that clinicians may have in agreeing on the definition of milder forms, especially regarding severe neurodevelopmental disorders. Prospective studies of *FOXG1* patients or the description of a larger cohort would be necessary to overcome these biases.

In conclusion, some patients with *FOXG1* P/LP variants can walk unassisted and acquire speech, particularly in association with missense variants located in the FHD. Other determinants, such as genetic background, epigenetic landscapes, or environmental factors may also play a role and warrant further exploration. This information could be used to refine prognosis after the identification of *FOXG1* variants in young children and to facilitate the interpretation of novel *FOXG1* variants identified after exome/genome sequencing.

AUTHOR CONTRIBUTIONS

Benoit Mazel wrote the manuscript and was responsible for data collection. Julian Delanne, Aurore Garde, Caroline Racine, Ange-Line

Bruel, Yannis Duffourd, Diego Lopergolo, Filippo Maria Santorelli, Viviana Marchi, Anna Maria Pinto, Maria Antonietta Mencarelli, Roberto Canitano, Floriana Valentino, Filomena Tiziana Papa, Chiara Fallerini, Francesca Mari, Alessandra Renieri, Arnold Munnich, Tanguy Niclass, Gwenaël Le Guyader, Christel Thauvin-Robinet, and Christophe Philippe contributed to the clinical and/or biological data collection. Laurence Faivre contributed to the clinical data collection, writing, review, and editing of the manuscript. All authors reviewed and approved the latest version of the manuscript.

ACKNOWLEDGMENTS

We thank the patients and their families for taking part in the study. Several authors are part of the European Reference Network ITHACA. The authors wish to thank Suzanne Rankin (Dijon Bourgogne University Hospital) for reviewing the English manuscript. We also thank Ricerca Corrente 5X1000 (to F.M.S.).

FUNDING INFORMATION

This work was supported by grants from Dijon University Hospital and the European Union through the FEDER programs.

CONFLICT OF INTEREST STATEMENT

The authors declare no conflicts of interest.

DATA AVAILABILITY STATEMENT

The data that support the findings of this study are available from the corresponding author upon reasonable request.

ORCID

Benoit Mazel  <https://orcid.org/0000-0002-1788-1495>

Aurore Garde  <https://orcid.org/0000-0003-3196-0453>

Laurence Faivre  <https://orcid.org/0000-0001-9770-444X>

REFERENCES

- Akol, I., Gather, F., & Vogel, T. (2022). Paving therapeutic avenues for *FOXG1* syndrome: Untangling genotypes and phenotypes from a molecular perspective. *International Journal of Molecular Sciences*, 23(2), 954. <https://doi.org/10.3390/ijms23020954>
- Allou, L., Lambert, L., Amsellem, D., Bieth, E., Ederly, P., Destrée, A., Rivier, F., Amor, D., Thompson, E., Nicholl, J., Harbord, M., Nemos, C., Saunier, A., Moustaine, A., Vigouroux, A., Jonveaux, P., & Philippe, C. (2012). 14q12 and severe Rett-like phenotypes: New clinical insights and physical mapping of *FOXG1*-regulatory elements. *European Journal of Human Genetics*, 20(12), 1216–1223. <https://doi.org/10.1038/ejhg.2012.127>
- Ariani, F., Hayek, G., Rondinella, D., Artuso, R., Mencarelli, M. A., Spanhol-Rosseto, A., Pollazzon, M., Buoni, S., Spiga, O., Ricciardi, S., Meloni, I., Longo, I., Mari, F., Broccoli, V., Zappella, M., & Renieri, A. (2008). *FOXG1* is responsible for the congenital variant of Rett syndrome. *American Journal of Human Genetics*, 83(1), 89–93. <https://doi.org/10.1016/j.ajhg.2008.05.015>
- Bahi-Buisson, N., Nectoux, J., Girard, B., Van Esch, H., De Ravel, T., Boddaert, N., Plouin, P., Rio, M., Fichou, Y., Chelly, J., & Bienvenu, T. (2010). Revisiting the phenotype associated with *FOXG1* mutations: Two novel cases of congenital Rett variant. *Neurogenetics*, 11(2), 241–249. <https://doi.org/10.1007/s10048-009-0220-2>
- Cellini, E., Vignoli, A., Pisano, T., Falchi, M., Molinaro, A., Accorsi, P., Bontacchio, A., Pinelli, L., Giordano, L., Guerrini, R., & *FOXG1* Syndrome Study Group. (2016). The hyperkinetic movement disorder of

- FOXG1-related epileptic-dyskinetic encephalopathy. *Developmental Medicine and Child Neurology*, 58(1), 93–97. <https://doi.org/10.1111/dmnc.12894>
- Collins, B. E., & Neul, J. L. (2022). Rett syndrome and *MECP2* duplication syndrome: Disorders of *MECP2* dosage. *Neuropsychiatric Disease and Treatment*, 18, 2813–2835. <https://doi.org/10.2147/NDT.S371483>
- De Filippis, R., Pancrazi, L., Bjørge, K., Rosseto, A., Kleefstra, T., Grillo, E., Panighini, A., Cardarelli, F., Meloni, I., Ariani, F., Mencarelli, M. A., Hayek, J., Renieri, A., Costa, M., & Mari, F. (2012). Expanding the phenotype associated with *FOXG1* mutations and in vivo *FoxG1* chromatin-binding dynamics. *Clinical Genetics*, 82(4), 395–403. <https://doi.org/10.1111/j.1399-0004.2011.01810.x>
- Frullanti, E., Papa, F. T., Grillo, E., Clarke, A., Ben-Zeev, B., Pineda, M., Bahi-Buisson, N., Bienvenu, T., Armstrong, J., Roche Martinez, A., Mari, F., Nissenkorn, A., Lo Rizzo, C., Veneselli, E., Russo, S., Vignoli, A., Pini, G., Djuric, M., Bisgaard, A. M., ... Renieri, A. (2019). Analysis of the phenotypes in the Rett networked database. *International Journal of Genomics*, 2019, 6956934. <https://doi.org/10.1155/2019/6956934>
- Hettige, N. C., & Ernst, C. (2019). *FOXG1* dose in brain development. *Frontiers in Pediatrics*, 7, 482. <https://doi.org/10.3389/fped.2019.00482>
- Jang, H. N., Kim, T., Jung, A. Y., Lee, B. H., Yum, M. S., & Ko, T. S. (2021). Identification of *FOXG1* mutations in infantile hypotonia and postnatal microcephaly. *Medicine*, 100(47), e27949. <https://doi.org/10.1097/MD.00000000000027949>
- Khan, A. A., & Kirmani, S. (2020). Mild presentation of the congenital variant Rett syndrome in a Pakistani male: Expanding the phenotype of the forkhead box protein G1 spectrum. *Clinical Dysmorphology*, 29(2), 111–113. <https://doi.org/10.1097/MCD.0000000000000302>
- Kortüm, F., Das, S., Flindt, M., Morris-Rosendahl, D. J., Stefanova, I., Goldstein, A., Horn, D., Klopocki, E., Kluger, G., Martin, P., Rauch, A., Roumer, A., Saitta, S., Walsh, L. E., Wieczorek, D., Uyanik, G., Kutsche, K., & Dobyns, W. B. (2011). The core *FOXG1* syndrome phenotype consists of postnatal microcephaly, severe mental retardation, absent language, dyskinesia, and corpus callosum hypogenesis. *Journal of Medical Genetics*, 48(6), 396–406. <https://doi.org/10.1136/jmg.2010.087528>
- Kumamoto, T., & Hanashima, C. (2017). Evolutionary conservation and conversion of *Foxg1* function in brain development. *Development, Growth & Differentiation*, 59(4), 258–269. <https://doi.org/10.1111/dgd.12367>
- Le Guen, T., Fichou, Y., Nectoux, J., Bahi-Buisson, N., Rivier, F., Boddaert, N., Diebold, B., Héron, D., Chelly, J., & Bienvenu, T. (2011). A missense mutation within the fork-head domain of the forkhead box G1 gene (*FOXG1*) affects its nuclear localization. *Human Mutation*, 32(2), E2026–E2035. <https://doi.org/10.1002/humu.21422>
- Mencarelli, M. A., Spanhol-Rosseto, A., Artuso, R., Rondinella, D., De Filippis, R., Bahi-Buisson, N., Nectoux, J., Rubinsztajn, R., Bienvenu, T., Moncla, A., Chabrol, B., Villard, L., Krumina, Z., Armstrong, J., Roche, A., Pineda, M., Gak, E., Mari, F., Ariani, F., & Renieri, A. (2010). Novel *FOXG1* mutations associated with the congenital variant of Rett syndrome. *Journal of Medical Genetics*, 47(1), 49–53. <https://doi.org/10.1136/jmg.2009.067884>
- Méneret, A., Mignot, C., An, I., Habert, M. O., Jacquette, A., Vidailhet, M., Bienvenu, T., & Roze, E. (2012). Generalized dystonia, athetosis, and parkinsonism associated with *FOXG1* mutation. *Movement Disorders: Official Journal of the Movement Disorder Society*, 27(1), 160–161. <https://doi.org/10.1002/mds.23956>
- Mitter, D., Pringsheim, M., Kaulisch, M., Plümacher, K. S., Schröder, S., Warthemann, R., Abou Jamra, R., Baethmann, M., Bast, T., Büttel, H. M., Cohen, J. S., Conover, E., Courage, C., Eger, A., Fatemi, A., Grebe, T. A., Hauser, N. S., Heinritz, W., Helbig, K. L., ... Brockmann, K. (2018). *FOXG1* syndrome: Genotype-phenotype association in 83 patients with *FOXG1* variants. *Genetics in Medicine: Official Journal of the American College of Medical Genetics*, 20(1), 98–108. <https://doi.org/10.1038/gim.2017.75>
- Philippe, C., Amsellem, D., Francannet, C., Lambert, L., Saunier, A., Verneau, F., & Jonveaux, P. (2010). Phenotypic variability in Rett syndrome associated with *FOXG1* mutations in females. *Journal of Medical Genetics*, 47(1), 59–65. <https://doi.org/10.1136/jmg.2009.067355>
- Richards, S., Aziz, N., Bale, S., Bick, D., Das, S., Gastier-Foster, J., Grody, W. W., Hegde, M., Lyon, E., Spector, E., Voelkerding, K., Reh, H. L., & ACMG Laboratory Quality Assurance Committee. (2015). Standards and guidelines for the interpretation of sequence variants: A joint consensus recommendation of the American College of Medical Genetics and Genomics and the Association for Molecular Pathology. *Genetics in Medicine: Official Journal of the American College of Medical Genetics*, 17(5), 405–424. <https://doi.org/10.1038/gim.2015.30>
- Terrone, G., Bienvenu, T., Germanaud, D., Barthez-Carpentier, M. A., Diebold, B., Delanoe, C., Passemard, S., & Auvin, S. (2014). A case of Lennox-Gastaut syndrome in a patient with *FOXG1*-related disorder. *Epilepsia*, 55(11), e116–e119. <https://doi.org/10.1111/epi.12800>
- Toresson, H., Martinez-Barbera, J. P., Bardsley, A., Caubit, X., & Krauss, S. (1998). Conservation of *BF-1* expression in amphioxus and zebrafish suggests evolutionary ancestry of anterior cell types that contribute to the vertebrate telencephalon. *Development Genes and Evolution*, 208(8), 431–439. <https://doi.org/10.1007/s004270050200>
- Van der Aa, N., Van den Bergh, M., Ponomarenko, N., Verstraete, L., Ceulemans, B., & Storm, K. (2011). Analysis of *FOXG1* is highly recommended in male and female patients with Rett syndrome. *Molecular Syndromology*, 1(6), 290–293. <https://doi.org/10.1159/000330755>
- Vegas, N., Cavallin, M., Maillard, C., Boddaert, N., Toulouse, J., Schaefer, E., Lerman-Sagie, T., Lev, D., Magalie, B., Moutton, S., Haan, E., Isidor, B., Heron, D., Milh, M., Rondeau, S., Michot, C., Valence, S., Wagner, S., Hully, M., ... Bahi-Buisson, N. (2018). Delineating *FOXG1* syndrome: From congenital microcephaly to hyperkinetic encephalopathy. *Neurology Genetics*, 4(6), e281. <https://doi.org/10.1212/NXG.0000000000000281>
- Wong, L. C., Singh, S., Wang, H. P., Hsu, C. J., Hu, S. C., & Lee, W. T. (2019). *FOXG1*-related syndrome: From clinical to molecular genetics and pathogenic mechanisms. *International Journal of Molecular Sciences*, 20(17), 4176. <https://doi.org/10.3390/ijms20174176>
- Wong, L. C., Wu, Y. T., Hsu, C. J., Weng, W. C., Tsai, W. C., & Lee, W. T. (2019). Cognition and evolution of movement disorders of *FOXG1*-related syndrome. *Frontiers in Neurology*, 10, 641. <https://doi.org/10.3389/fneur.2019.00641>
- Xuan, S., Baptista, C. A., Balas, G., Tao, W., Soares, V. C., & Lai, E. (1995). Winged helix transcription factor *BF-1* is essential for the development of the cerebral hemispheres. *Neuron*, 14(6), 1141–1152. [https://doi.org/10.1016/0896-6273\(95\)90262-7](https://doi.org/10.1016/0896-6273(95)90262-7)

SUPPORTING INFORMATION

Additional supporting information can be found online in the Supporting Information section at the end of this article.

How to cite this article: Mazel, B., Delanne, J., Garde, A., Racine, C., Bruel, A.-L., Duffourd, Y., Loperogolo, D., Santorelli, F. M., Marchi, V., Pinto, A. M., Mencarelli, M. A., Canitano, R., Valentino, F., Papa, F. T., Fallerini, C., Mari, F., Renieri, A., Munnich, A., Niclass, T., ... Faivre, L. (2024). *FOXG1* variants can be associated with milder phenotypes than congenital Rett syndrome with unassisted walking and language development. *American Journal of Medical Genetics Part B: Neuropsychiatric Genetics*, 195B:e32970. <https://doi.org/10.1002/ajmg.b.32970>