

The “Skull Flap” a new conceived device for decompressive craniectomy/cranioplasty: Feasibility study on cadaver specimen

[Salvatore Chibbaro](#), [L. Tigan](#), [M. Marsella](#),³ [B. George](#),¹ [R. Galzio](#),⁴ [P. Kehrl](#), [E. Vicaut](#),² and [P. Diemidio](#)

Department of Neurosurgery, Strasbourg University Hospital, Strasbourg, France

¹*Department of Neurosurgery, Lariboisiere University Hospital, Paris, France*

²*Clinical Research Unit, Lariboisiere Hospital – Fernand Widal, Paris, France*

³*Private Neurosurgeon (affiliated with University Arizona Medical Center), Arizona, United States, Arizona*

⁴*Department of Neurosurgery, L'Aquila University Hospital, Aquila, Italy*

Address for correspondence: Dr. Salvatore Chibbaro, Department of Neurosurgery, Strasbourg University Hospital, 1, Av Moliere, 67100 Strasbourg, France. E-mail: schibbaro@hotmail.com

Copyright : © Journal of Neurosciences in Rural Practice

This is an open-access article distributed under the terms of the Creative Commons Attribution-Noncommercial-Share Alike 3.0 Unported, which permits unrestricted use, distribution, and reproduction in any medium, provided the original work is properly cited.

Abstract

Background:

Decompressive craniectomy (DC) is a procedure that is currently performed with increasing frequency. The reason is that its indications have become much broader. This procedure may be associated with the relevant morbidity in the postoperative stage due to the creation of a large bone defect. On the other hand, cranioplasty is associated too with some of the common complications related to any reconstructive head surgery. The authors present a newly developed device: The “Skull Flap” (SF). This new device allows the surgeon to complete a DC, yet providing at the same time a cranial reconstruction that will not require the patient to undergo a second reconstructive procedure.

Materials and Methods:

Different size and location craniectomies were carried out on four human cadaveric heads; the bone flaps were then repositioned in a more elevated position with respect to the skull edges. The flaps were placed at a distance of 12 and 15 mm from the skull edges using the SF system. Crash tests were conducted on each flap while in open and closed positions to assess its reliability and efficacy.

Results:

SF was shown to be a strong fixation device that allows satisfactory brain decompression by keeping the original bone flap away from the swollen brain; at the same time, in a later stage, it allows cranial reconstruction in a simple way.

Conclusion:

The SF device was shown to be very easy to use, adaptable, and practical to apply; thus, allowing both satisfactory brain decompression as well as bone flap repositioning at a later time after the brain swelling has subsided.

Keywords: Cranioplasty, decompressive craniectomy, new device and technique, skull flap

Introduction

Currently, decompressive craniectomy is indicated in cases of intractable raised intracranial pressure resulting from severe head injury, subarachnoid and intracerebral hemorrhage, malignant brain ischemic stroke, extensive cerebral venous sinus thrombosis, and in many other conditions responsible for life-threatening brain swelling (i.e., tumor, etc.).[1,2,3,4,5,6,7,8,9,10,11,12] Generally, the bone flap removed is stored in a bone bank or in the patient abdominal fat; if the bone flap has to be discarded, then reconstruction using various biomaterials (acrylic resin, porous hydroxyapatite, titanium plate, etc.) is an excellent alternative that allows to complete a cranioplasty later on. In the acute phase of brain swelling, a wide craniectomy allows brain protection from likely irreversible damage.[13] While a decompressive craniectomy is usually carried out with a sense of urgency, there is usually a long waiting period before reconstruction is entertained. While waiting to complete a cranioplasty with a considerable delay (1-12 months),[14,15] several problems may arise due to the presence of a skull defect. Some of these problems include:

- Direct brain injury due to the lack of protective bone layer
- Brain hemodynamic and metabolic derangement resulting in neurological and cognitive deterioration[16,17,18,19,20,21,22]
- Delayed rehabilitation
- New onset of psychological problems due to poor cosmesis.
- Last but not least, patients require a second operation (cranioplasty) with all the associated and potential risks and costs related to another surgery.[23,24]

In this paper, the authors present a newly conceived device that brings about the benefits of a decompressive craniectomy and at the same time spare patients from requiring a second, usually delayed reconstructive surgery.

Materials and Methods

Description of system

The “Skull Flap” (SF) device is a permanent implant; it is manufactured according to International Organization for Standardization 5832-3 and it is made of titanium ASTM F 136, grade 3.7165, tensile min 860, max 9999 Mpa that maintains optimal biocompatibility and allows optimal compatibility with CT and MRI.

The SF consists of a hinge system that is connected to one edge of the removed bone flap to the skull. The opposite edge of the bone flap is connected to the skull by a plate/sliding track that carries a locking–unlocking system [Figures 1–4]. This plate is also connected to a titanium wire tunneled and externalized in the scalp at a site distant from the surgical and covered by a silicon tube. Within 2-4 weeks, when the brain swelling has subsided, the wire will serve as traction for the repositioning of the flap in its anatomical position. To unlock the system, a peculiar maneuver is needed and specifically pulling the wire first downward, and subsequently, upward while it is right on the major flap axis to avoid accidental release. The plate and the hinge will also allow bony fusion of the flap edges.

Methods

Different size and location craniectomies were completed in four different human cadaveric heads (a total of eight craniectomies were made) and the elevated bone flaps were repositioned and locked 12 and 15 mm higher from the skull edge using the SF system [Figures 5 and 6]. The authors have empirically chosen the height of 12-15 mm from the outer skull layer thinking that a large craniectomy (i.e., 12 × 15 cm), as they routinely do in real patient, could assure an adequate decompression and in the meantime gaining a sufficient expansion volume thanks to the large surface. Load-bearing testing of the craniectomies were completed using the universal test machine Zwick 1485 (Zwick, Inc., Ulm, Germany), applying a defined quasi-static ($V = 5$ mm/min) mechanical force. The impression ratio to the submitted force was automatically recorded until reaching a 2-mm flap descent while in the open position and a 2-mm depth while in closed position.

The present study has been approved by the hospital IRB (Institutional Research Board).

The SF prototype assessed in this study was shown to be very easy to use, adaptable, and applicable to craniectomies of various types and size. The results of the load-bearing tests are showed in a graphic [[Figure 7](#)]. The result clearly demonstrates that the SF is a strong fixation device with optimal plastic deformability allowing a satisfactory and consistent brain decompression. In our study, the bone flap remained very well in the desired raised position. Furthermore, the fact that an edge of the device is directly attached to the skull guarantees the repositioning of the flap back in its correct anatomical position; as well as the lock–unlock system has demonstrated a reliable and very efficient flap descent once unlocked. It is important to note that we were able to perfectly reapproximate the scalp over the raised flap when kept at heights between 12 and 15 mm. Since the scalp of cadaveric heads can be well closed, it is our opinion that this is also possible in living patients as the skin is much more elastic and extensible.

Discussion

Decompressive craniectomy is a procedure performed with increasing frequency worldwide and its indications have been extended to a large number of conditions.[[1,2,3,4,5,6,7,8,9,10,11,12](#)] The main idea and guiding principle of the SF system is to allow decompressive craniectomy maintaining at the same time the flap in place (though desirably raised between 12 and 15 mm from the brain surface). This allows to achieve a dual goal: (1) satisfactory brain decompression followed by (2) repositioning of the flap in its anatomical position (usually after 2-4 weeks) simply pulling a wire rather than performing a new surgical procedure.

Such a system may also potentially avoid all the problems related to a skull defect such as direct brain injury, delayed patient's rehabilitation, local and global brain hemodynamics and metabolic dysfunction leading to neurological deterioration,[[16,17,18,19,20,21](#)] patient's psychological problems due to poor cosmetics, and, above all, surgery for cranial reconstruction.[[23,24](#)] To our knowledge, there are no similar systems currently available in the international market. It has already been proposed by some surgeons the possibility of using inverted “L”-shaped mini-plates to keep the bone elevated, although this technique necessarily require a reintervention for their removal and for the repositioning of the bone flap; others have proposed to leave the bone flap floating above the brain,[[25,26](#)] although this system, we do believe, does not guarantee an effective cerebral decompression and it may also cause the formation of adhesions between the flap and the underlying tissues (brain and dura mater) preventing proper repositioning and favoring pseudo-artrosis. Analyzing more in details the SF device we believe that it has two relative limitations.

Under some circumstance, it may be difficult to close the skin over the flap in an elevated position (although we were able to close the skin in all eight craniectomies with the flap raised up to 15 mm) even if the scalp retains optimal elasticity. Brain decompression may be suboptimal at the site where the flap is attached to the skull with the hinge; this problem prompted a modification of the SF device, which is currently in progress. This is a modification that will allow equal bone flap elevation all around the craniotomy edges thus allowing equal decompression.

Conclusion

The SF device was shown to be a very easy, adaptable, and practical device. It is a strong fixing device with, at the same time, optimal plastic deformability allowing reliable brain decompression; this is because the bone flap remains in an elevated position and pulls easily back in its anatomical position thus completing a cranial reconstruction. SF presents also some limitations currently under study and requires modification. Next stage will be an experimental study on an animal model to assess safety of the SF device (already in progress on dogs) before the possible implementation in a clinical study to assess its real efficacy in human patients.

Footnotes

Source of Support: Nil.

References

1. Chibbaro S, Di Rocco F, Mirone G, Fricia M, Makiese O, Di Emidio P, et al. Decompressive craniectomy and early cranioplasty for the management of severe head injury: A prospective multicenter study on 147 patients. *World Neurosurg.* 2011;75:558–62. [PubMed: 21600512]
2. Chibbaro S, Tacconi L. Role of decompressive craniectomy in the management of severe head injury with refractory cerebral edema and intractable intracranial pressure. Our experience with 48 cases. *Surg Neurol.* 2007;68:632–8. [PubMed: 17765952]
3. Chibbaro S, Marsella M, Romano A, Ippolito S, Benericetti E. Combined internal uncrusectomy and decompressive craniectomy for the treatment of severe closed head injury: Experience with 80 cases. *J Neurosurg.* 2008;108:74–9. [PubMed: 18173313]
4. Vahedi K, Vicaut E, Mateo J, Kurtz A, Orabi M, Guichard JP, et al. DECIMAL Investigators. Sequential-design, multicenter, randomized, controlled trial of early decompressive craniectomy in malignant middle cerebral artery infarction (DECIMAL Trial) *Stroke.* 2007;38:2506–17. [PubMed: 17690311]
5. Vahedi K, Hofmeijer J, Juettler E, Vicaut E, George B, Algra A, et al. DECIMAL, DESTINY, and HAMLET investigators. Early decompressive surgery in malignant infarction of the middle cerebral artery: A pooled analysis of three randomised controlled trials. *Lancet Neurol.* 2007;6:215–22. [PubMed: 17303527]
6. Guerra WK, Gaab MR, Dietz H, Mueller JU, Piek J, Fritsch MJ. Surgical decompression for traumatic brain swelling: Indications and results. *J Neurosurg.* 1999;90:187–96. [PubMed: 9950487]
7. Maas AI, Dearden M, Teasdale GM, Braakman R, Cohadon F, Iannotti F, et al. EBIC guidelines for management of severe head injury in adults: European brain injury consortium. *Acta Neurochir.* 1997;139:286–94. [PubMed: 9202767]
8. Jennett B. Epidemiology of severe head injury: Socioeconomic consequence of avoidable mortality and morbidity. In: Scriabine A, Teasdale GM, Tettenborn D, Young W, editors. *Nimodipine. Pharmacological and clinical results in cerebral ischemia.* Berlin: Springer; 1991. pp. 225–33.
9. Marshall LF. Head injury: Past, present and future. *Neurosurgery.* 2000;47:546–61. [PubMed: 10981741]
10. Arikan F, Vilalta J, Romero FJ, Porta I, Martínez-Ricarte FR, Sahuquillo J. Primary decompressive craniectomy in patients with aneurysmatic subarachnoid hemorrhage. Results of a pilot study in 11 cases. *Neurocirugia (Astur)* 2010;21:452–60. [PubMed: 21165542]
11. Ferro JM, Crassard I, Coutinho JM, Canhão P, Barinagarrementeria F, Cucchiara B, et al. Second international study on cerebral vein and dural sinus thrombosis (ISCVT 2) investigators. Decompressive surgery in cerebrovenous thrombosis: A multicenter registry and a systematic review of individual patient data. *Stroke.* 2011;42:2825–31. [PubMed: 21799156]
12. Théaudin M, Crassard I, Bresson D, Saliou G, Favrole P, Vahedi K, et al. Should decompressive surgery be performed in malignant cerebral venous thrombosis?: A series of 12 patients. *Stroke.* 2010;41:727–31. [PubMed: 20185780]
13. DeWitt DS, Jenkins JW, Prough DS. Enhanced vulnerability to secondary ischemic insults after experimental traumatic brain injury. *New Horiz.* 1995;3:376–83. [PubMed: 7496745]
14. Boström S, Bobinski L, Zsigmond P, Theodorsson A. Improved brain protection at decompressive craniectomy: A new method using Palacos R-40 (methylmethacrylate) *Acta Neurochir.* 2005;147:279–81. [PubMed: 15662564]
15. Kawaguchi T, Hosoda K, Shibata Y, Koyama J. Expanded polytetrafluoroethylene membrane for

- prevention of adhesion in patients undergoing external decompression and subsequent cranioplasty. *Neurol Med Chir (Tokyo)* 2003;43:320–3. [PubMed: 12870554]
16. Yamaura A, Makino H. Neurological deficits in the presence of the sinking flap following decompressive craniectomy. *Neurol Med Chir.* 1977;17:43–53.
17. Schaller B, Graf R, Sanada Y, Rosner G, Wienhard K, Heiss WD. Hemodynamic and metabolic effects of decompressive hemicraniectomy in normal brain. An experimental PET-study in cats. *Brain Res.* 2003;982:31–7. [PubMed: 12915237]
18. Sakamoto S, Eguchi K, Kiura Y, Arita K, Kurisu K. CT perfusion imaging in the syndrome of the sinking skin flap before and after cranioplasty. *Clin Neurol Neurosurg.* 2006;108:583–5. [PubMed: 15921849]
19. Winkler PA, Stummer W, Linke R, Krishnan KG, Tatsch K. Influence of cranioplasty on postural blood flow regulation, cerebrovascular reserve capacity, and cerebral glucose metabolism. *J Neurosurg.* 2000;93:53–61. [PubMed: 10883905]
20. Winkler PA, Stummer W, Linke R, Krishnan KG, Tatsch K. The influence of cranioplasty on postural blood flow regulation, cerebrovascular reserve capacity, and cerebral glucose metabolism. *Neurosurg Focus.* 2000;8:e9. [PubMed: 16924777]
21. Chibbaro S, Vallee F, Beccaria K, Poczos P, Makiese O, Fricia M, et al. The impact of early cranioplasty on cerebral blood flow and its correlation with neurological and cognitive outcome. Prospective multi-centre study on 24 patients. *Rev Neurol (Paris)* 2013;169:240–8. [PubMed: 23084153]
22. Chibbaro S, Fricia M, Vallee F, Beccaria K, Poczos P, Mateo J, et al. The impact of early cranioplasty on cerebral blood flow and metabolism and its correlation with neurological and cognitive outcome: Prospective multi-center study on 34 patients. *Indian J Neurosurg.* 2012;1:17–22.
23. Dujovny M, Aviles A, Agner C, Fernandez P, Charbel FT. Cranioplasty: Cosmetic or therapeutic? *Surg Neurol.* 1997;47:238–41. [PubMed: 9068693]
24. Stiver SI. Complications of decompressive craniectomy for traumatic brain injury. *Neurosurg Focus.* 2009;26:E7. [PubMed: 19485720]
25. Peethambaran AK, Valsalmony J. Four-quadrant osteoplastic decompressive craniotomy: A novel technique for decompressive craniectomy avoiding revision cranioplasty after surgery. *Neurol India.* 2012;60:672–4. [PubMed: 23287349]
26. Adeleye AO, Azeez AL. Decompressive craniectomy bone flap hinged on the temporalis muscle: A new inexpensive use for an old neurosurgical technique. *Surg Neurol Int.* 2011;2:150. [PMCID: PMC3205509] [PubMed: 22059143]

Figures and Tables

Figure 1



SF system model in open position

Figure 2




SF system model in open position

Figure 3



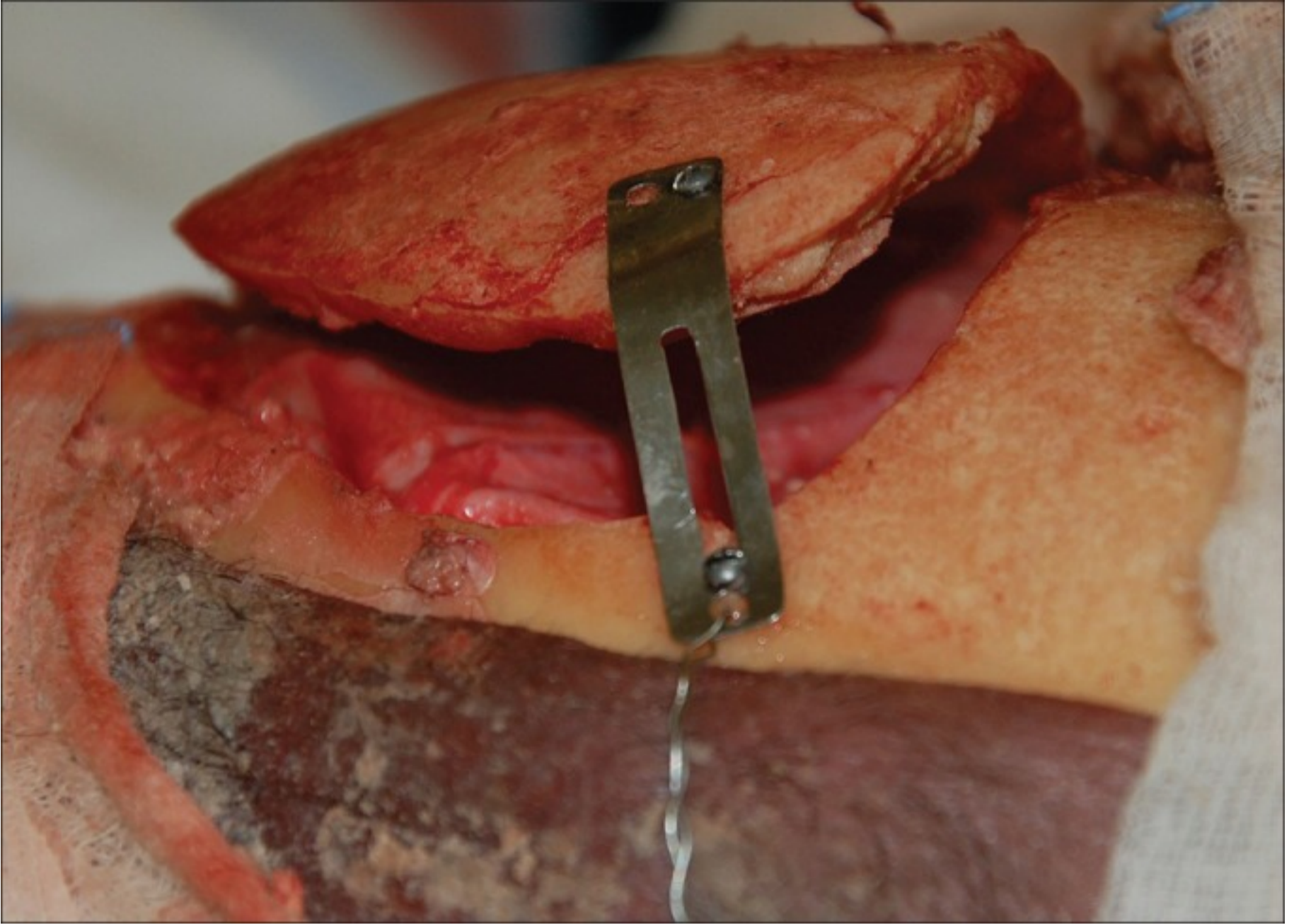
SF system in closed position

Figure 4



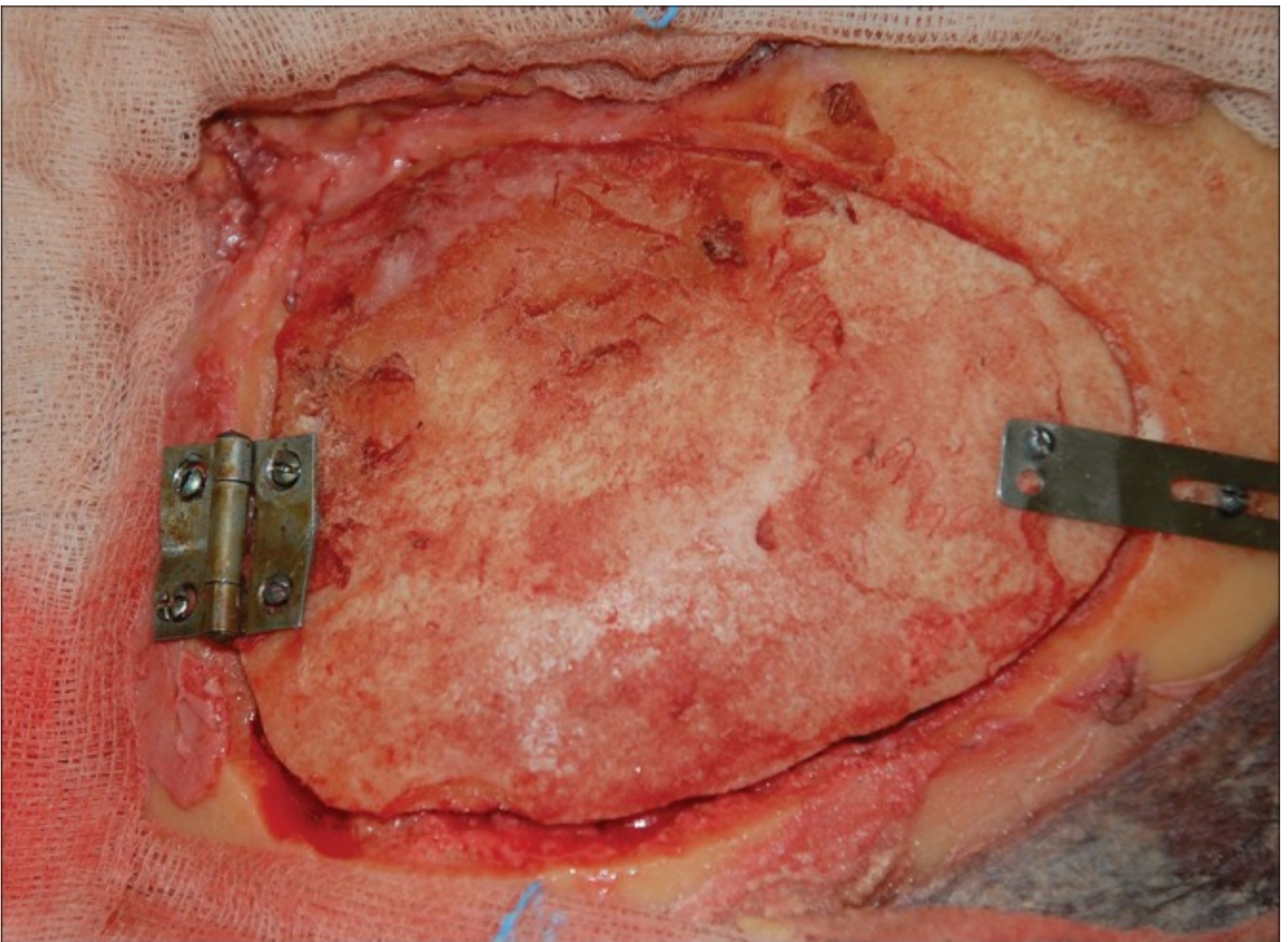
Prototype of SF device conceived and designed for experimental study on dogs (being currently in progress)

Figure 5



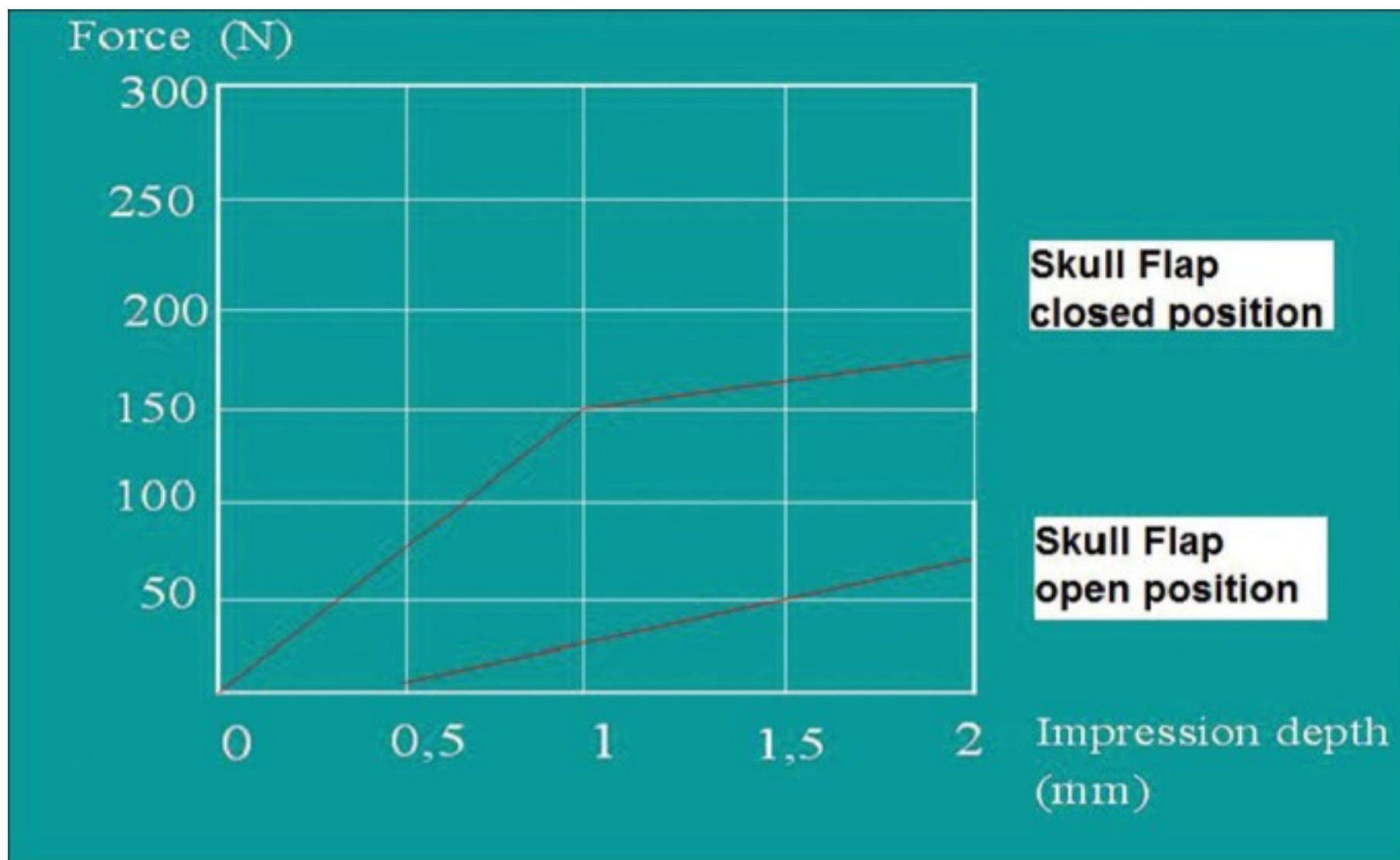
Fronto-parietal craniotomy showing the SF device in place keeping the bone flap in an open position

Figure 6



Fronto-parietal craniotomy showing the SF device in place keeping the bone flap in a closed position

Figure 7



Graphic showing the load-bearing test on SF device demonstrating that it is needed 70 N = 70 kg of impression force to make 2 mm descent of the bone in an open position as well as 175 N = 175 kg of impression force to make 2 mm descent of the bone in a closed position