

Conjunctival Modifications in Ocular Hypertension and Primary Open Angle Glaucoma: An In Vivo Confocal Microscopy Study

Marco Ciancaglini, Paolo Carpineto, Luca Agnifili, Mario Nubile, Vincenzo Fasanella, and Leonardo Mastropasqua

PURPOSE. The study was conducted to analyze, by in vivo confocal microscopy (IVCM), the conjunctival epithelial characteristics in untreated ocular hypertension (OH) and in topically treated primary open-angle glaucoma (POAG).

METHODS. The study included 30 eyes affected with untreated OH, 96 eyes with POAG receiving medical therapy, and 15 healthy control eyes. The main outcome measures were the mean density and the mean area of conjunctival epithelium microcysts. The relations among the microscopic parameters intraocular pressure (IOP), and age in both hypertensive and glaucomatous eyes and between mean defect (MD) of visual fields and the time on therapy in patients with glaucoma were analyzed.

RESULTS. There was no evidence of conjunctival microcysts in any of the healthy eyes examined; conversely, conjunctival microcysts were found in all ocular hypertensive eyes (mean microcyst density of 19.7 ± 3.5 cysts/mm² and mean total microcyst area of 4063.6 ± 921.2 μ m²). All patients with POAG showed conjunctival microcysts (mean density of 28.7 ± 2.7 cysts/mm² and a mean total microcyst area of 6564.2 ± 671.4 μ m²). No significant differences were found between OH and POAG subjects for microcyst parameters and no significant relations were found in either OH or POAG eyes for microcyst density, area, IOP, MD, and time on therapy.

CONCLUSIONS. The results of the study show that conjunctival microcysts are features present in all hypertensive and glaucomatous eyes. Based on these findings, conjunctiva could be an additional potential target tissue available for the investigation by a noninvasive in vivo approach of glaucoma-induced pathologic modifications. (*Invest Ophthalmol Vis Sci.* 2008;49:3042–3048) DOI:10.1167/iovs.07-1201

Microscopic modifications of ocular tissues have been widely documented in patients affected with primary open-angle glaucoma (POAG), both in aqueous inflow and outflow pathways (ciliary body, trabecular meshwork, Schlemm's canal and suprachoroidal space) and in neuroretinal system (optic nerve head neural rim, retinal nerve fiber layer and lamina cribrosa).^{1–3} Moreover, in a chronic disease such as glaucoma, the necessity of a long-term medical management with topical medications frequently leads to important changes

in ocular surface tissues, particularly the conjunctiva. For the most part, these changes are certainly due to the toxic action of both active compounds and preservatives.^{4,5} Several studies have been conducted to evaluate the toxicity of antiglaucoma drugs in the conjunctival epithelium in patients in long-term treatment^{6,7} and have reported either a direct drug toxicity on epithelial cells or an indirect action on the lacrimal film. All reports available in the literature have widely and exclusively investigated the conjunctival toxic changes induced by topical therapy.^{5–9} Nonetheless, to date, no study has been conducted to analyze possible conjunctival modifications directly induced by the physiopathologic mechanisms related to the onset and/or progression of POAG and ocular hypertension (OH).

Currently, impression cytology¹⁰ and laser scanning in vivo confocal microscopy (IVCM) are widely used and are considered reliable diagnostic methods for microscopic analysis of ocular surface tissues. However IVCM has rarely been used to investigate and describe the characteristics of normal conjunctiva. Only one study in which epithelial microcyst-like structures were found exclusively in the tarsal conjunctiva has been reported.¹¹ Conversely, IVCM has been used mainly in post-surgical filtering bleb analysis, to distinguish functioning from nonfunctioning trabeculectomies on the basis of selected epithelial and connective parameters, but has not thus far been valuable.^{12–15} More recently, in a data set of medically treated patients with glaucoma undergoing trabeculectomy who were scheduled to undergo IVCM conjunctival examination on the superior bulbar conjunctiva before and after the surgical procedures (MC, unpublished data, 2007), we also found conjunctival epithelial microcysts before the trabeculectomy. Based on these findings, the purpose of our study was to use IVCM to analyze and describe the microscopic epithelial features of bulbar conjunctiva both in untreated patients with OH and treated patients with glaucoma.

MATERIAL AND METHODS

The study adhered to the tenets of the Declaration of Helsinki. Informed consent was obtained from all enrolled patients. We examined 126 eyes of 126 consecutive Caucasian subjects—30 eyes affected with untreated OH and 96 eyes affected with POAG in medical therapy—referred to the Ophthalmic Clinic of University Chieti-Pescara, Italy. Fifteen consecutive healthy eyes were used as control. The demographic characteristics of patients are reported in Table 1.

None of the normal subjects had a history of any topical or systemic therapy, nor had they been affected by any ocular or systemic diseases in the past 6 months. All eyes showed a best corrected visual acuity $\geq 8/10$, a refractive error ≤ 4 D (spherical equivalent), an intraocular pressure (IOP) lower than 20 mm Hg, corneal pachymetry ranging from 530 to 560 μ m, an absence of signs of glaucomatous optic neuropathy, and normal results in a visual field examination (Humphrey 30-2 full-threshold; Carl Zeiss Meditec, Oberkochen Germany). All hypertensive eyes were completely normal except for the IOPs, which ranged from 22 to 27 mm Hg (mean of three measurements at 9 AM, 12 noon, and 4 PM). Conversely, glaucomatous eyes had IOPs at

From the Department of Medicine and Ageing Science, Ophthalmic Clinic, University of Chieti-Pescara, Pescara, Italy.

Submitted for publication September 14, 2007; revised January 2 and February 1, 2008; accepted May 8, 2008.

Disclosure: **M. Ciancaglini**, None; **P. Carpineto**, None; **L. Agnifili**, None; **M. Nubile**, None; **V. Fasanella**, None; **L. Mastropasqua**, None

The publication costs of this article were defrayed in part by page charge payment. This article must therefore be marked "advertisement" in accordance with 18 U.S.C. §1734 solely to indicate this fact.

Corresponding author: Marco Ciancaglini, Piazza della Rinascita, 79, 65122 Pescara, Italy; m.ciancaglini@unich.it.

TABLE 1. Characteristics of the Patients and Groups

	Controls	OH	POAG
Mean age (y)	51.2 ± 6.3 (SD)	53.4 ± 7.4 (SD)	54.1 ± 8.3 (SD)
Sex (M/F)	7/8	14/16	45/51
Mean IOP (mm Hg)	14.3 ± 1.6 (SD)	24.1 ± 1.83 (SD)*	16.4 ± 2.01 (SD)†
Mean microcyst density (cysts/mm ²)	0	19.7 ± 3.5 (SE)	28.7 ± 2.7 (SE)
Mean total microcyst area (μm ²)	0	4063.6 ± 921.2 (SE)	6564.2 ± 671.4 (SE)

* $P < 0.001$ vs. control and POAG.

† $P = 0.009$ vs. control.

the time of diagnosis ranging from 22 to 34 mm Hg (mean of three measurements at 9 AM, 12 noon, and 4 PM), a full-threshold visual field test (Humphrey 30-2; Carl Zeiss Meditec) showing at least three contiguous points on the total deviation probability plot at the less than 2% level, Glaucoma Hemifield Test results outside normal limits, and classic ophthalmoscopic signs of glaucomatous optic neuropathy (cupping, neural rim notching, and saucerization). Only patients with glaucoma who were receiving topical hypotensive therapy that had started at least 6 months before the day of IVCM examination and had remained unmodified during the past 6 months were enrolled in the study. Moreover, none of the patients had a history of any topical or systemic diseases or therapies in the past 6 months, to avoid any significant interaction that could have occurred with ocular surface tissues. A history of using contact lenses was considered an exclusion criterion in all cases. Among patients with glaucoma, 28 were in monotherapy with topical β -blockers (group 1; 17 eyes with preserved timolol maleate 0.5% and 11 eyes with preserved levobunolol hydrochloride 0.5%), 46 were in monotherapy with prostaglandin analogues (group 2; 16 with latanoprost 0.005%, 15 with travoprost 0.004% and 15 with bimatoprost 0.03%), and 22 patients were in associative unfixed combination therapy (group 3; eight with latanoprost-timolol, six with travoprost-timolol, and eight with bimatoprost-timolol).

Each subject enrolled in the study, after a complete ophthalmic examination performed from 10 to 12 AM, including visual acuity evaluation, applanation tonometry, slit lamp biomicroscopy, gonioscopy, and funduscopy, was carefully examined with a digital confocal laser-scanning microscope (LSM; HRT II Cornea Module; Heidelberg Engineering GmbH, Heidelberg, Germany).

The technical characteristics of this instrument and the details of conjunctival examination have been described.¹⁶ The confocal assessment of bulbar conjunctiva in this case series was performed by placing the seated patient in front of the microscope, the head was set steady with a headrest, and the eye was properly aligned to obtain tangential optical sections of the superior and temporal bulbar conjunctiva, with a dedicated target mobile bright red light provided with the instrument that the patient had to fix with the fellow eye. A digital camera was used to acquire images of the lateral view of the eye and objective lens to check the position of the objective lens on the surface of the eye during each scan. The LSM objective was gently placed in contact with the ocular surface separated by a PMMA (polymethyl methacrylate) contact cap and a drop of 0.2% polyacrylic gel (Viscotirs Gel; CIBA Vision Ophthalmics, Marcon, Venezia, Italy) served as a coupling medium. Sequential images derived from automatic scans and manual frames were acquired throughout upper and temporal bulbar conjunctiva at the intermediate layer (10–20 μ m) of each examined eye.

For the IVCM assessment, we microscopically evaluated the bulbar conjunctiva on identifying epithelial microcysts (defined as intraepithelial and extracellular optically empty spaces), such as those reported in the conjunctival wall of functioning filtering blebs (Fig. 1).^{12–15} The main parameters considered in the IVCM examination were the mean microcyst density (cysts per square millimeters) and the total microcyst area (in square micrometers). The results were reported as the average of measures performed in the superior and temporal conjunctiva (from 3 to 6 mm from the limbus), analyzing six images (three in the superior conjunctiva and three in the temporal

conjunctiva; 300 × 300 μ m), selected by the IVCM operator (MN) in a masked fashion. The surface area of epithelial microcysts was calculated by using ImageJ, an open source software (<http://rsb.info.nih.gov/ij/> available by ftp at zippy.nimh.nih.gov/ or at <http://rsb.info.nih.gov/nih-image>; developed by Wayne Rasband, National Institutes of Health, Bethesda, MD), as described elsewhere.¹⁴

In addition, to verify the findings obtained in the sampled fields, we extended the analysis area to the whole conjunctival superior region in three OH eyes not included in the sample analysis, finally obtaining a planar reconstruction that showed the actual distribution of epithelial microcysts (Fig. 2).

The mean time of the IVCM examination from the onset of the disease was 27.1 ± 10.9 months (range, 6–42) and 41.3 ± 7.3 months (range, 12–64) in patients affected with OH and POAG, respectively.

Statistical Analysis

Analysis was performed with commercial software (SPSS Advanced Statistical Software ver. 13.0, 2005; Chicago, IL). Student's *t*-test and the χ^2 test were used to evaluate age and sex differences among healthy, hypertensive, and glaucomatous eyes. The Mann-Whitney test was performed to analyze the mean microcyst density and the total microcyst area in hypertensive and glaucomatous eyes. The Kruskal-Wallis or one-way ANOVA with Tukey post hoc analysis was used to evaluate the differences in the three groups of glaucomatous eyes with different topical therapies. Pearson's correlation was used to analyze the relation among conjunctival IVCM parameters (mean microcyst

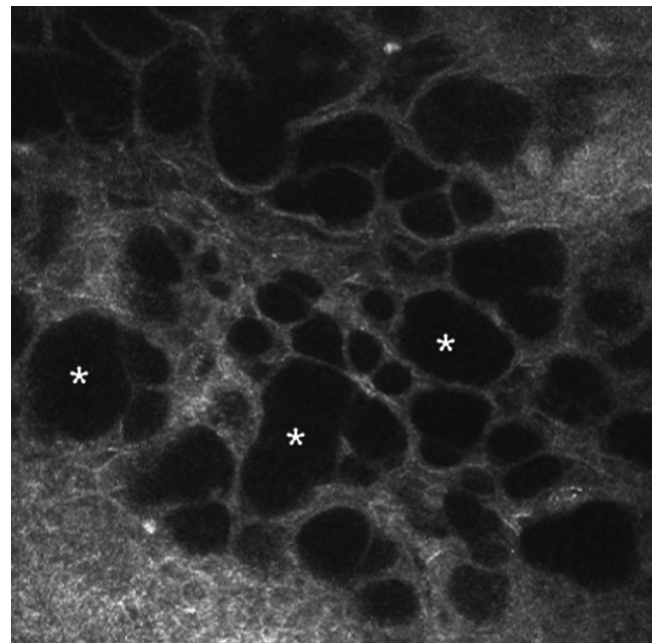


FIGURE 1. Epithelial features of a functioning filtering bleb showing conjunctival epithelium with numerous and wide fluid-filled hyporefective microcysts (*).




FIGURE 2. Planar reconstruction of the superior bulbar conjunctiva in a right eye with OH, showing the distribution of epithelial microcysts in the entire region. The final map was obtained by juxtaposing side by side each acquired image, consecutively moving the cornea module from the nasal to the temporal region (*right* and *left* side of the image, respectively) and from the limbus to the upper lid (*bottom* and *top* of the image, respectively).

density and the mean total microcyst area), IOP, and age in hypertensive and glaucomatous eyes and to examine the relation between ICVM parameters, mean defect (MD) of visual field and time on therapy only in glaucomatous eyes. A transformation using logarithms of mean microcyst density and area values was used in the statistical analysis to reduce the wide distribution of the sample data. The original data before transformation are shown in the Results section and tables.

RESULTS

The demographic and clinical data of each group are shown in Table 1. No significant differences were found in age and sex among the healthy, OH, and POAG eyes, whereas the IOPs in the glaucomatous eyes were significantly different from those in both OH and normal eyes.

In accordance with Messmer et al.,¹¹ when performing the ICVM examination of bulbar conjunctiva in healthy eyes in the intermediate epithelial layers, we found small cells with a polygonal shape, hyperreflective borders, and high uniformity in size and shape (Fig. 3). Conjunctival microcysts were not found in any subject.^{14,15}

Conversely and notably in hypertensive subjects, whereas epithelial features were not markedly different in comparison with those in healthy eyes (Fig. 4A), conjunctival microcysts were detected in all subjects. In these cases, intraepithelial microcysts appeared to be round or oval, with an optically clear aspect (dark appearance), due to the very low internal reflectivity (Fig. 4B). With regard to the main parameters analyzed, we documented a mean microcyst density of 19.7 ± 3.5 (mean \pm SE, cysts per square millimeter) and a mean total microcyst area of 4063.6 ± 921.2 (mean \pm SE, in square micrometers)—an expression of an evident and high interindividual variability.

Pearson's correlation did not indicate a significant relation among IOP, age, and density of microcysts ($r = 0.281$, $P = 0.401$ and $r = 0.271$, $P = 0.414$, respectively) or among IOP,

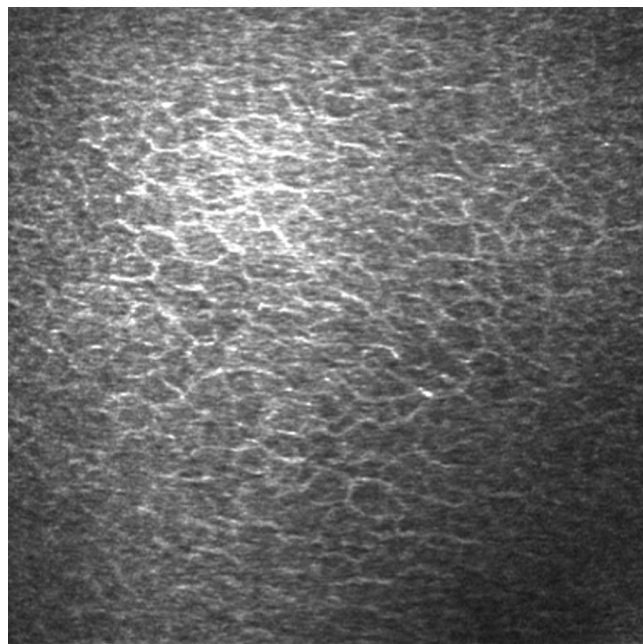


FIGURE 3. Epithelial features in healthy eyes. Regular appearance of the intermediate epithelial layers characterized by small cells with hyperreflective borders and a highly uniform size and polygonal shape, with no signs of disruption.

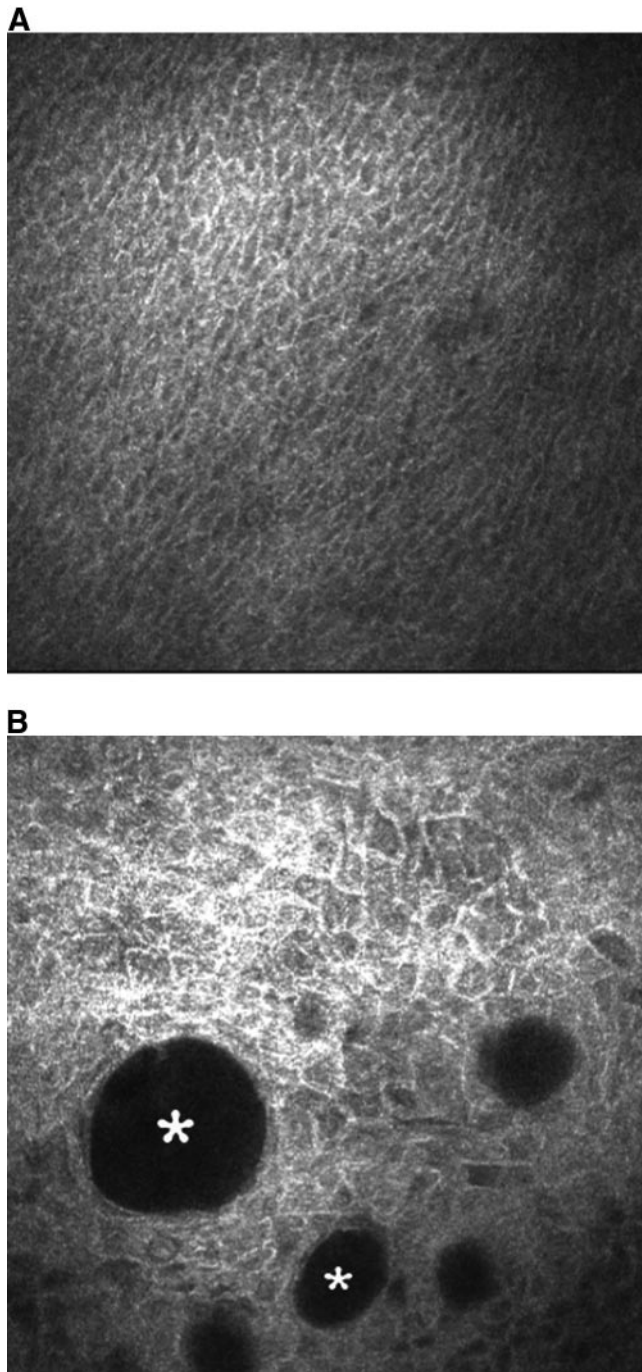


FIGURE 4. (A) Conjunctival epithelium in hypertensive eyes: regular appearance of the intermediate epithelial layers characterized by small cells with hyperreflective borders and a highly uniform size and polygonal shape. (B) Intraepithelial conjunctival microcysts in hypertensive eyes. Appearance of wide extracellular hyporefective spaces (*), different in size and round or oval in shape.

age, and total microcyst area ($r = 0.128$, $P = 0.6710$ and $r = 0.146$, $P = 0.525$, respectively) in hypertensive eyes.

In patients with glaucoma the characteristics of conjunctival epithelial cells were similar among the three groups, since very large and polygonal cells with markedly hyperreflective borders and low uniformity in size and shape (polymorphism and polymegethism) were documented (Fig. 5A). All glaucomatous eyes showed intraepithelial conjunctival microcysts, with the same characteristics described in the hypertensive

eyes (Figs. 5B–D); the mean microcyst density and the mean total microcyst area of the whole sample of glaucomatous eyes were 28.7 ± 2.7 (mean \pm SE, cysts per square millimeter) and 6564.2 ± 671.4 (mean \pm SE, square micrometers), respectively. These values were not significantly different from those reported in hypertensive eyes (Table 1). The IOP, age, MD, and time on therapy of patients with glaucoma did not correlate with the mean microcyst density ($r = 0.0025$, $P = 0.820$; $r = 0.185$, $P = 0.724$; $r = 0.249$, $P = 0.512$; and $r = 0.297$, $P = 0.147$ respectively) or the total microcyst area ($r = 0.101$, $P = 0.226$; $r = -0.045$, $P = 0.837$; $r = 0.215$, $P = 0.197$; and $r = 0.297$, $P = 0.126$, respectively).

When comparing the three groups of patients with glaucoma with different medical therapies, we found no significant differences in IOP, MD, and time on therapy, whereas we observed statistically significant differences in mean microcyst density ($P = 0.003$) and mean total microcyst area ($P < 0.001$; Table 2). The analysis of eyes on unfixed combination therapy (group 3, Fig. 4D) indicated that they had a microscopic pattern characterized by a significant greater mean microcyst density in comparison with prostaglandin/prostanoid-treated eyes (group 2, Fig. 4C; $P = 0.004$). Moreover, the patients on unfixed combination therapy (group 3, Fig. 4D) showed a significantly larger microcyst area than did eyes on monotherapy with either β -blocker (group 1) or prostaglandin (group 2; $P = 0.001$ and $P < 0.001$, respectively; Table 2).

DISCUSSION

Currently, conjunctival epithelial modifications in eyes that have undergone trabeculectomy were demonstrated by IVCM only at the site of filtering blebs.^{13,14} The presence of conjunctival epithelial microcysts has been considered a useful parameter in distinguishing functioning from nonfunctioning blebs.^{13,15} Nevertheless, none of the studies that analyzed this aspect had a control group of healthy eyes or included examination of the conjunctiva before surgery. Therefore, whether the presence of conjunctival microcysts is a feature linked just to the surgical procedure rather than an expression of the glaucomatous disease or the therapy was not analyzed. The results of our study contribute to clarifying these aspects.

First, the presence on bulbar conjunctiva of structures showing the characteristics of conjunctival microcysts was not a feature of normal subjects, since the IVCM examination did not show microscopic aspects of optically clear conjunctival spaces in any of the healthy control eyes. This result is in accordance with those of a recent study reported by Messmer et al.¹¹ which described tiny subepithelial microcysts containing inflammatory cells only within the normal tarsal conjunctiva.

Conversely, all the eyes in which an impairment of the hydrodynamic aqueous system were hypothesized,^{1,2} either affected with OH or glaucoma, showed clear evidence of conjunctival modifications that appeared greater, though not statistically significant, in glaucomatous eyes. Of note, when analyzing the effect of IOP on the conjunctival parameters considered, we did not find a statistically significant correlation between OH or glaucoma cases with control IOP, suggesting that the microcyst formation process could not be directly induced by IOP-related inner mechanical forces and could still be active, even if the medical therapy was effective in reducing IOP. On the other hand, the analysis of the relation between the different medical therapies for glaucomatous eyes and conjunctival microcyst parameters produced conflicting results. We found a higher microcyst density in β -blocker/prostaglandin unfixed combination users when compared with prostaglandin users, whereas the microcyst area showed

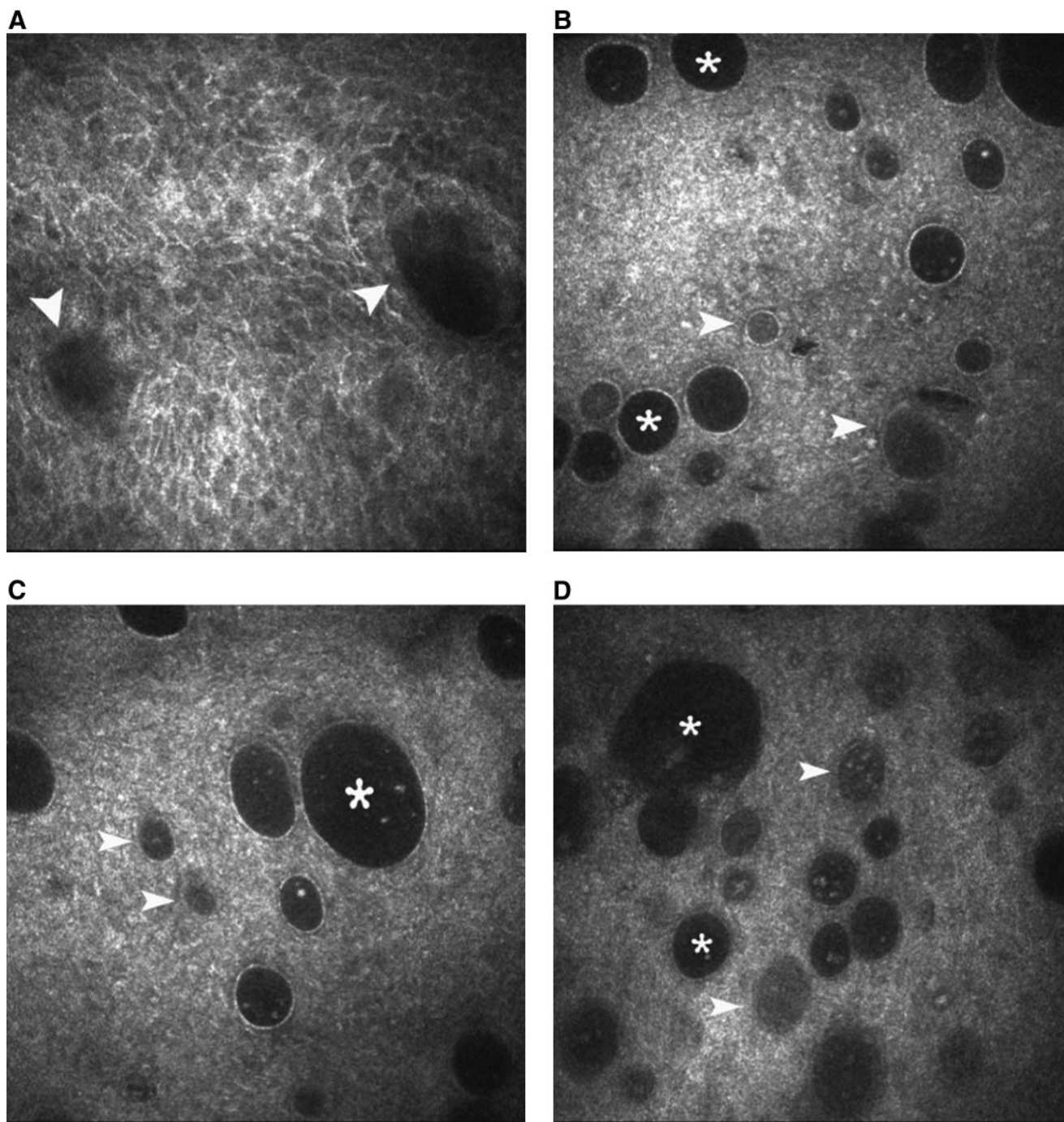


FIGURE 5. (A) Epithelial features in glaucomatous eyes. Patchy appearance of the intermediate epithelial layers with evident signs of cellular polymorphism and polymegethism and with marked hyperreflective borders. Aspects of poorly defined epithelial microcysts are detectable as two dark round hyporeflective structures (*arrowheads*). (B) Intraepithelial conjunctival microcysts in a glaucomatous eye treated with a topical β -blocker. The image shows both encapsulated epithelial microcysts with open lumens (*) and those filled with amorphous material (*arrowhead*); a high microcyst density is clearly visible. (C) Intraepithelial conjunctival microcysts in a glaucomatous eye treated topical prostaglandins or prostanoids. Also in this group of patients, there was an appearance of wide encapsulated extracellular hyporeflective spaces, alternatively presenting open lumens (*) or filled with amorphous material (*arrowhead*). This group of eyes showed a lower microcyst density. (D) Intraepithelial conjunctival microcysts in a glaucomatous eye treated with topical combined therapy (β -blockers+prostaglandins or prostanoids). The eyes in this group showed both epithelial microcysts with open lumens (*) and those filled with amorphous material (*arrowhead*). The wide surface of the microcysts is easily visualized by ICVM.

higher values in glaucomatous eyes on combined β -blocker/prostaglandin therapy in comparison with all eyes on monotherapy.

However, the ability of our study to estimate the influence of each class of treatment on described conjunctival modifica-

tions was limited, because the study was not specifically designed to compare differences between treatment groups. Therefore, it was not possible to exclude bias in evaluating the results of different topical treatment, and the significance of this finding requires further investigation.

TABLE 2. Characteristics of the Glaucomatous Patients in Therapy

	Group 1 (β -blockers)	Group 2 (Prostaglandins/ Prostanoids)	Group 3 (β -Blockers+Prostaglandins/ Prostanoids)
Mean microcyst density (cysts/mm ²)	36.1 \pm 10.0 (SE)	20.3 \pm 2.5 (SE)	40.2 \pm 5.0 (SE)*
Mean total microcyst area (μ m ²)	4,654.2 \pm 1,063.8 (SE)	4,591.3 \pm 609.3 (SE)	11,319.6 \pm 1,610.2 (SE)†
Mean IOP (mm Hg)	15.4 \pm 2.6 (SD)	16.8 \pm 1.9 (SD)	16.1 \pm 2.8 (SD)
MD of visual field (dB)	-5.4 \pm 2.3 (SD)	-6.0 \pm 2.5 (SD)	-6.2 \pm 3.6 (SD)
Mean time on therapy (mo)	25.2 \pm 9.2 (SD)‡	32.8 \pm 9.8 (SD)	34.5 \pm 8.7 (SD)

* $P = 0.004$ vs. group 2.† $P = 0.001$ vs. group 1 and $P < 0.001$ vs. group 2.‡ $P = 0.003$ and $P = 0.002$ vs. group 2 and group 3, respectively.

In addition, the potential toxic effect of the preservative contained in the ophthalmic solutions (mainly benzalkonium chloride; BAC) has to be carefully considered as a potential factor involved in structural tissue modifications. Of interest, the presence of conjunctival microcysts in untreated hypertensive eyes did not support the hypothesis that microcyst formation could be exclusively related to an unpredictable effect of BAC. On the other hand, we cannot completely exclude that a higher dosage of BAC, as in patients receiving combined therapy, is an additional factor involved in the development of a greater microcyst area, as observed in this group of patients. Based on this hypothesis, the topical preservative toxicity may act as an accessory mechanism that contributed to and perhaps enhanced microcyst formation independent of the main mechanism of induction.

Based on the results achieved in our study, we theorized that the presence of epithelial microcysts in hypertensive and glaucomatous eyes could be related to one of the possible hydrodynamic pathways activated in hyperbaric ocular conditions instead of a side effect of antiglaucoma drugs or preservatives on conjunctival epithelium.

A stimulating hypothesis was that the presence of conjunctival microcysts could be linked to an increasing aqueous flow through the sclera in eyes with reduced trabecular meshwork outflow. Several studies in human and animal eyes^{17–22} have demonstrated that uveoscleral outflow compromises transscleral flow, bulk flow around the emissaria, and absorption into the choroidal vessels. Jackson et al.²³ showed that the potential human transscleral outflow facility in vitro is 0.33 μ L/min/mm Hg in the suprachoroidal space and, assuming a pressure of 13 mm Hg in this site, a flow of 4.3 μ L/min through the sclera has been calculated. This value is markedly higher than those found in vivo (1.1–1.5 μ L/min).²⁴ The discrepancy is due to the presence of natural barriers impeding the outflow, located at the stromal tissue of the drainage angle and at the ora serrata. Consequentially, the suprachoroidal pressure is approximately 4 mm Hg lower than the anterior chamber pressure (IOP). An increase in IOP results in a nonlinear increase in suprachoroidal pressure and may result in transscleral outflow.²⁵

However, this hypothesis must be confirmed by supplementary evidence, because our study had some limitations. First, histologic verifications of the IVCM findings, which were in vivo aspects, are needed. Second, an experimental animal model is needed to assess the dynamic of conjunctival microcyst formation. Third, the knowledge of the real topical therapy effect could be better estimated by analyzing the conjunctiva of patients with glaucoma before and after drug administration. And finally, further studies are needed to prove the specificity of conjunctival microcysts as a sign of glaucoma by studying their possible presence in other ocular¹¹ or systemic diseases.

In conclusion, the results of our report indicate that conjunctiva could be a potential target tissue useful in assessing

pathologic modifications directly induced by glaucomatous disease, by using a noninvasive method.

References

1. Civan MM, Macknight ADC. The ins and outs of aqueous humor secretion. *Exp Eye Res.* 2004;78:625–631.
2. Johnson M. What controls aqueous humour outflow resistance? *Exp Eye Res.* 2006;82:545–557.
3. Quigley HA. Neuronal death in glaucoma. *Prog Retin Eye Res.* 1998;18:39–57.
4. Arici MK, Arici DS, Topalkara A, Güler C. Adverse effects of topical antiglaucoma drugs on the ocular surface. *Clin Exp Ophthalmol.* 2000;28:113–117.
5. Baudouin C, Hamard P, Liang H, Creuzot-Garcher C, Bensoussan L, Brignole F. Conjunctival epithelial cell expression of interleukins and inflammatory markers in glaucoma patients treated over the long term. *Ophthalmology.* 2004;111:2186–2192.
6. Rolando M, Brezzo G, Giordano P, et al. The effect of different benzalkonium chloride concentrations on human normal ocular surface: a controlled prospective impression cytology study. In: Van Bijsterweld OP, Lemp MA, Spinelli D, eds. *The Lacrimal System*. Amsterdam: Kugler & Ghedini; 1991:89–91.
7. De Saint Jean M, Brignole F, Bringuier AF, Bauchet A, Feldmann G, Baudouin C. Effects of benzalkonium chloride on growth and survival of Chang conjunctival cells. *Invest Ophthalmol Vis Sci.* 1999;40:619–630.
8. Baudouin C, Pisella PJ, Goldschild M, et al. Ocular surface inflammatory changes induced by topical antiglaucoma drugs: human and animal studies. *Ophthalmology.* 1999;3:556–563.
9. Mietz H, Niesen U, Krieglstein GK. The effects of preservatives and antiglaucomatous medication on histopathology of the conjunctiva. *Graefes Arch Clin Exp Ophthalmol.* 1994;32:561–565.
10. Singh R, Joseph A, Umapathy T, Tint NL, Dua HS. Impression cytology of the ocular surface. *Br J Ophthalmol.* 2005;89:1655–1659.
11. Messmer EM, Mackert MJ, Zapp DM, Kampik A. In vivo confocal microscopy of normal conjunctiva and conjunctivitis. *Cornea.* 2006;25:781–788.
12. Labbé A, Dupas B, Hamard P, Baudouin C. Étude en microscopie confocale *in vivo* des bulles de filtration après chirurgie du glaucome. *J Fr Ophthalmol.* 2004;27:1083–1089.
13. Labbé A, Dupas B, Hamard P, Baudouin C. In vivo confocal microscopy study of blebs after filtering surgery. *Ophthalmology.* 2005;112:1979.
14. Messmer EM, Zapp DM, Mackert MJ, Thiel M, Kampik A. In vivo confocal microscopy of filtering blebs after trabeculectomy. *Arch Ophthalmol.* 2006;124:1095–1103.
15. Guthoff R, Klink T, Schlunck G, Grehn F. In vivo confocal microscopy of failing and functioning filtering blebs: results and clinical correlations. *J Glaucoma.* 2006;15:552–558.
16. Mastropasqua L, Nubile M, Lanzini M, Carpineto P, Toto L, Ciancaglini M. Corneal and conjunctival manifestations in Fabry disease: in vivo confocal microscopy study. *Am J Ophthalmol.* 2006;141:709–718.

17. Toris CB, Gregerson DS, Pederson JE. Uveoscleral outflow using different-sized fluorescent tracers in normal and inflamed eyes. *Exp Eye Res.* 1987;45:525-532.
18. Bill A. Conventional and uveoscleral drainage of aqueous humour in the cynomolgus monkey (*Macaca irus*) at normal and high intraocular pressures. *Exp Eye Res.* 1966;5:45-54.
19. Wood RL, Koseki T, Kelly DE. Uveoscleral permeability to intracamerally infused ferritin in eyes of rabbits and monkeys. *Cell Tissue Res.* 1992;270:559-567.
20. Bill A. The routes for bulk drainage of aqueous humour in rabbits with and without cyclodialysis. *Doc Ophthalmol.* 1966;20:157-169.
21. Gelatt KN, Gum GG, Williams LW, Barries KP. Uveoscleral flow of aqueous humor in the normal dog. *Am J Vet Res.* 1979;40:845-848.
22. Krohn J, Bertelsen T. Corrosion casts of the suprachoroidal space and uveoscleral drainage routes in the pig eye. *Acta Ophthalmol Scand.* 1997;75:28-31.
23. Jackson TL, Hussain A, Hodgetts A et al. Human scleral hydraulic conductivity: age-related changes, topographical variation, and potential scleral outflow facility. *Invest Ophthalmol Vis Sci.* 2006;47:4942-4946.
24. Toris CB, Yablonsky ME, Wang YL, Camras CB. Aqueous humor dynamics in the ageing human eyes. *Am J Ophthalmol.* 1999;127:407-412.
25. Emi K, Pederson JE, Toris CB. Hydrostatic pressure of the suprachoroidal space. *Invest Ophthalmol Vis Sci.* 1989;30:233-238.