[1]Department of Intensive Care, St-Luc University Clinics, Catholic University of Louvain, Brussels, Belgium; [2]Cardiac Intensive Care Unit, St-Luc University Clinics, Catholic University of Louvain, Brussels, Belgium

*Corresponding author: Philippe Hantson, Department of Intensive Care, St-Luc University Clinics, Avenue Hippocrate 10, 1200 Brussels, Belgium.
E-mail: philippe.hantson@uclouvain.be

References

1. Buckley NA, Dawson AH, Isbister GK. Serotonin syndrome. BMJ 2014;348:g1626.

2. Boyer EW, Shannon M. The serotonin syndrome. N Engl J Med 2005;352:1112–20.

3. Girard P, Coppé MC, Verniers D, Pansart Y, Gillardin JM. Role of catecholamines and serotonin receptor subtypes in nefopam-induced antinociception. Pharmacol Res 2006;54:195–202.

4. Kim KH, Abdi S. Rediscovery of nefopam for the treatment of neuropathic pain. Korean J Pain 2014;27:103–11.

5. Durrieu G, Olivier P, Bagheri H, Montastruc JL; French Network of Pharmacovigilance Centers. Overview of adverse reactions to nefopam: an analysis of the French Pharmacovigilance database. Fundam Clin Pharmacol 2007;21:555–8.

Conflicts of interest.—The authors certify that there is no conflict of interest with any financial organization regarding the material discussed in the manuscript.

Article first published online: January 4, 2019. - Manuscript accepted: December 17, 2018. - Manuscript revised: November 29, 2018. - Manuscript received: October 22, 2018.

(*Cite this article as:* Trungu J, Laarbaui F, Dechamps M, Hantson P. Rapidly fatal neurological and cardiocirculatory failure in a patient recently treated with nefopam. Minerva Anestesiol 2019;85:561-2. DOI: 10.23736/S0375-9393.18.13395-5)

Online version at http://www.minervamedica.it
Minerva Anestesiologica 2019 May;85(5):562-3
DOI: 10.23736/S0375-9393.19.13476-1

The perpendicular sacral plexus block: an alternative approach to the sacral plexus

The sacral plexus block is of fundamental importance for analgesia in hip replacement surgery.

It can also be used as a substitute for spinal anesthesia, when associated with the lumbar plexus block in patients with hip fracture, in which the conventional technique can be dangerous.[1, 2] One of the most well-known approaches to the lumbar plexus is represented by the "parasacral parallel shift" (PSPS) approach.[3] This technique is extremely useful for identifying the greater sciatic foramen and the sacral plexus from which it emerges. Furthermore, it can be used to identify the piriformis muscle for antalgic techniques involved in the treatment of chronic pain.[4]

On the other hand, the technique could be hard to be performed because of the depth of the structures, both for the difficulty in visualizing them and in following the needle to the target structure. Failure to visualize the tip of the needle may result in a vascular and nervous structures damage as well as in a wrong needle entering into the pelvic cavity.[5]

With this in mind, for the identification of the sacral plexus we propose a variant of the PSPS approach: the "perpendicular sacral plexus block," that we have successfully performed in a 79-year-old, obese (BMI 39.7) woman (ASA physical status 4) with a history of coronary artery disease in dual antiplatelet therapy (clopidogrel 75 mg + acetylsalicylic acid 100 mg) and severe aortic stenosis. The patient was scheduled to undergo total hip arthroplasty (THA) for femoral neck fractures.

Considering the high anesthesiologic risk, we decided to perform a combined lumbar and sacral plexus block, as a sole anesthetic method, in order to avoid the use of general or spinal anesthesia.

Peripheral venous access was obtained and ECG, HR, SpO2, non-invasive blood pressure (NIBP) were monitored, then the patient was placed in the lateral position with the limb to be treated facing upwards. After careful skin disinfection and draping, the antalgic procedure was performed.

A convex probe (3-5 Mhz) was placed in the middle third between the iliac crest and the greater trochanter. In this way the profile of the Iliac bone, the gluteus medius muscle and the gluteus minimus muscle were visualized. Subsequently, the probe was moved perpendicularly along the profile of the iliac bone till its interruption at the greater sciatic foramen.

With appropriate tilting movements of the transducer, the Sciatic nerve was identified in long-axis, while it emerges from the foramen.

Once the best visualization was obtained, a block needle was inserted using an in-plane technique and a cephalocaudal direction, making sure to move the needle towards the bone edge of the greater sciatic notch, where the sciatic nerve runs. This helped to avoid the damage of the ureter or rectum and the puncture of the inferior gluteal artery, what can happen if the needle is introduced in the pelvis beyond the plexus (Figure 1).[5]

Once the nervous target was reached, the electro-neuro-stimulator was turned on, and when muscle contractions were aroused at 0.2-0.4 mA, 15 mL of 0.5% levobupivacaine were injected.

Subsequently, we proceeded with the US-guided Lumbar Plexus Block using the "Shamrock Method."[6] At this point, 15 mL of 0.5% levobupivacaine were injected.

This approach allowed us to avoid the need for gen-

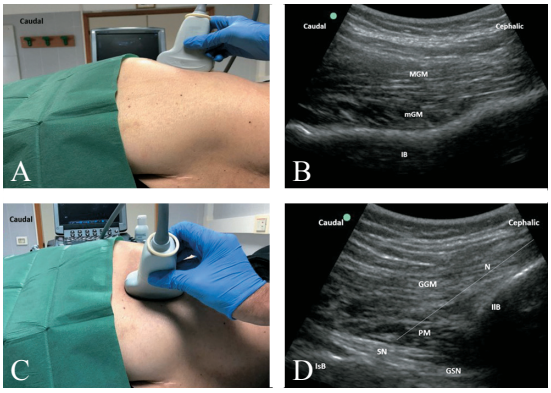

Figure 1.—A) The transducer is placed in the middle third between the iliac crest and the greater trochanter. The corresponding ultrasound scan B) demonstrates the continuous, hyperechoic iliac bone line upon which the gluteus medius muscle and the gluteus minimus muscle can be visualized; C) we can observe the final probe position; the corresponding ultrasound scan (D) demonstrates the needle (N) in its final position after passing through the gluteus maximus muscle and the piriformis muscle, with the tip close to the sciatic nerve (SN) that comes out of the greater sciatic foramen (GSN). IsB: edge of the the ischial bone; IlB: profile of the iliac bone.

eral anesthesia, ensuring an excellent hemodynamic stability and a lower risk of morbidity and mortality.

On the basis of our clinical experience, this approach could be useful since it would allow a simpler visualization of the target structures, particularly in obese or large elderly patients where other approaches had proved to be less valid.

Moreover, it can help to identify the Sciatic nerve in long axis, making it much easier to place a catheter in its proximity, without needing to change the position of the probe or rotate it.

We believe that our approach can be of great help in the execution of the sacral plexus blockade. In particular, the described technique could help those less experienced reduce the display time of the structures and facilitate the success of the performance.

Pierfrancesco FUSCO [1], Stefano DI CARLO [2] *, Giuseppe PALADINI [3], Paolo SCIMIA [4], Emiliano PETRUCCI [1], Franco MARINANGELI [5]

[1]Intensive Care Unit, Department of Anesthesia, San Salvatore Academic Hospital of L'Aquila, L'Aquila, Italy; [2]Department of Medical, Oral and Biotechnological Sciences, University of Chieti, Chieti, Italy; [3]Intensive Care Unit, Department of Anesthesia, F. Del Ponte Hospital, A.S.S.T. Settelaghi, Varese, Italy; [4]Department of Anesthesia and Perioperative Medicine, A.S.S.T. of Cremona, Cremona, Italy; [5]Department of Life, Health and Environmental Sciences, University of L'Aquila, L'Aquila, Italy

*Corresponding author: Stefano Di Carlo, Intensive Care Unit, Department of Anesthesia and, University of Chieti, Via Vetoio, 67100 L'Aquila, Italy. E-mail: stefanodik87@gmail.com

References

1. Ho AM, Karmakar MK. Combined paravertebral lumbar plexus and parasacral sciatic nerve block for reduction of hip fracture in a patient with severe aortic stenosis. Can J Anaesth 2002;49:946–50.

2. Petchara S, Paphon S, Vanlapa A, Boontikar P, Disya K. Combined Lumbar-Sacral Plexus Block in High Surgical Risk Geriatric Patients undergoing Early Hip Fracture Surgery. Malays Orthop J 2015;9:28–34.

3. Bendtsen TF, Lönnqvist PA, Jepsen KV, Petersen M, Knudsen L, Børglum J. Preliminary results of a new ultrasound-guided approach to block the sacral plexus: the parasacral parallel shift. Br J Anaesth 2011;107:278–80.

4. Fusco P, Di Carlo S, Scimia P, Degan G, Petrucci E, Marinangeli F. Ultrasound-guided Dry Needling Treatment of Myofascial Trigger Points for Piriformis Syndrome Management: A Case Series. J Chiropr Med 2018;17:198–200.

5. Ghisi D, Delaunay L, Fanelli A. Use of ultrasound for lower extremity. Curr Opin Anaesthesiol 2014;27:528–37.

6. Sauter AR, Ullensvang K, Bendtsen TF, Børglum J. The "ShamrockMethod" - a new and promising technique for ultrasound guided lumbar plexus blocks; 2013 [Internet]. Available from: https://academic.oup.com/bja/article/doi/10.1093/bja/el_9814/2451455 [cited 2019, Mar 13].

Conflicts of interest.—The authors certify that there is no conflict of interest with any financial organization regarding the material discussed in the manuscript.

Manuscript accepted: January 14, 2019. - Manuscript received: November 24, 2018.

(*Cite this article as:* Fusco P, Di Carlo S, Paladini G, Scimia P, Petrucci E, Marinangeli F. The perpendicular sacral plexus block: an alternative approach to the sacral plexus. Minerva Anestesiol 2019;85:562-3. DOI: 10.23736/S0375-9393.19.13476-1)