Received: 7 April 2021 | Revised: 30 May 2021 | Accepted: 13 June 2021
DOI: 10.1002/oa.3019

SHORT REPORT

Bilateral fabella in the mummy of the Blessed Jean Bassand (c. 1360–1445): A unique description in ancient human remains

Luca Ventura[1,2] | Federico Bruno[2] | Antonio Barile[2] | Carlo Masciocchi[2]

[1]Division of Pathology, San Salvatore Hospital, L'Aquila, Italy
[2]Department of Biotechnological and Applied Clinical Sciences, University of L'Aquila, L'Aquila, Italy

Correspondence
Luca Ventura, MD, Division of Pathology, San Salvatore Hospital, Coppito, L'Aquila 67100, Italy.
Email: lucaventura67@gmail.com

Abstract

Objectives: We report an ancient case of bilateral fabella, diagnosed in the mummified body of the Blessed Jean Bassand, dating back to the 15th century.

Materials and Methods: The mummy belonged to an elderly subject and underwent canonical recognition by external inspection, digital radioscopic and X-ray examination and computed tomography (CT) scanning.

Results: Plain films, CT scans and visual inspection displayed two bilateral, discrete, rounded osseous structures with regular cortical profile, projecting in the posterosuperior aspect of the lateral femoral condyles. Based on the location and anatomical features, the structures were identified as fabellae.

Discussion: To the best of our knowledge, this case represents the first description of fabella in ancient human remains, as well as the most ancient documented report of this sesamoid bone in human history, dating back the condition to the 15th century.

KEYWORDS
fabella, mummy, paleoradiology, sesamoid bone

1 | INTRODUCTION

Fabella is a sesamoid bone in the posterolateral aspect of the knee. It may be either bony or cartilaginous and is located in the anterior gliding surface of the lateral head of the gastrocnemius muscle, often articulating with the lateral femoral condyle (Dalip et al., 2018; Hou et al., 2019). A bony fabella can be easily identified in plain lateral radiographs of the knee, whereas a cartilaginous one is more difficult to be distinguished from the surrounding tissues (Agathangelidis et al., 2016).

This sesamoid bone can prevent friction-induced damage of the tendon, increase gastrocnemius efficiency, and cooperate with the fabellofibular ligament. Such functions are thought to be of help in the stabilization of the medial femoral condyle and the fabella complex (plantaris and gastrocnemius muscles, and the arcuate, fabellofibular, fabellopopliteal, and oblique popliteal ligaments) (Hou et al., 2019).

To the best of our knowledge, fabella has never been described in human osteoarchaeological settings. The present study aims to report a bilateral fabella found during scientific investigation of the mummified body belonged to the Blessed Jean Bassand, dating back to 15th century.

2 | MATERIAL

Born in Besançon (Franche Comté), Jean Bassand (c. 1360–1445) was a monk (Ventura et al., 2019; Ventura & Gaeta, 2020) and a leading figure in the French Celestine congregation, a branch of the Benedictine Order (Shaw, 2018). In 1443, he went to Aquila (now L'Aquila) by order of Pope Eugenius IV, to reform the monastery of Santa Maria di Collemaggio, where he died on 26 August 1445. His body, covered with lime to be displayed in the Basilica before the funeral ceremony, was found intact 18 years after (Ventura et al., 2019; Ventura & Gaeta, 2020). The Holy See beatified Jean Bassand in 1909. Since his death the mummy of Jean Bassand used to be kept in the Basilica of Collemaggio, within the altar of the left apse, closed by a painted hatch. The first known Canonical Recognition of

the body took place in 2019 (Ventura et al., 2019). The mummy appeared still fully dressed, with face and hands uncovered. The skin surface was extremely well preserved, possibly due to lime dehydration of the corpse after death (Figure 1).

3 | METHODS

After preliminary external inspection, the partially skeletonized mummy was submitted to digital radioscopic and X-ray examination on anteroposterior projection with a General Electric Prestige SI device and lateral projection using a General Electric Proteus XR/i device. Plain films of the skull, chest, upper and lower limbs, spine and pelvis were acquired.

The tomographic study was performed using a multidetector 320-row computed tomography (CT) scanner (Aquilion One, Toshiba) with the acquisition of 7,200 images. Acquisition parameter was as follows: field of view (FOV) of 50 × 59 cm, gantry rotation time of 0.5 s, slice thickness 0.5 mm, 120 kV and 50 mA/s. The entire body was scanned. Multiple intensity projection (MIP) and coronal and sagittal multiplanar reconstructions (MPRs) were performed to better analyse the mummy. Volumetric (3D) rendering was used to obtain views of the overall external aspects of the mummy. Manual or semi-automated techniques were also used to remove specific tissues or to create cutting planes.

Data were stored as a bitmap file in Digital Imaging and Commutations in Medicine (DICOM) format and processed, displayed and segmented using a Picture Archiving and Communication System (PACS) software (Carestream Health, USA).

A second visual inspection was performed after imaging studies interpretation. Although severely limited by mummified soft tissues and joint structures, the age at death was estimated by cranial suture closure (Meindl & Lovejoy, 1985) and dental wear pattern (Lovejoy, 1985).

4 | RESULTS

Plain film of the knees showed the presence of two bilateral, discrete, rounded osseous structures, with regular cortical profile, projecting in the posterosuperior aspect of the lateral femoral condyles. CT confirmed the presence and location of the bilateral and symmetric osseous structures, measuring 12 (right) and 15 mm (left), respectively (Figures 2 and 3). CT analysis also confirmed the osseous cortical-marrow bone interface. At the posterior femoral condyles bilaterally, was also evident the presence of a levelled bone marrow hyperdensity (Figure 2). No evidence of knee osteoarthritis was found.

A closer visual inspection of the popliteal region allowed to confirm the presence of the sesamoid bones embedded in fibrous tissue at the posterior aspect of the lateral femoral condyle (Figure 4). Based on the location and anatomical features, the structures were identified as fabellae. Age at death of the individual was estimated to be 50–60 years.

FIGURE 1 The mummified body at the beginning of the recognition. Left foot was missing

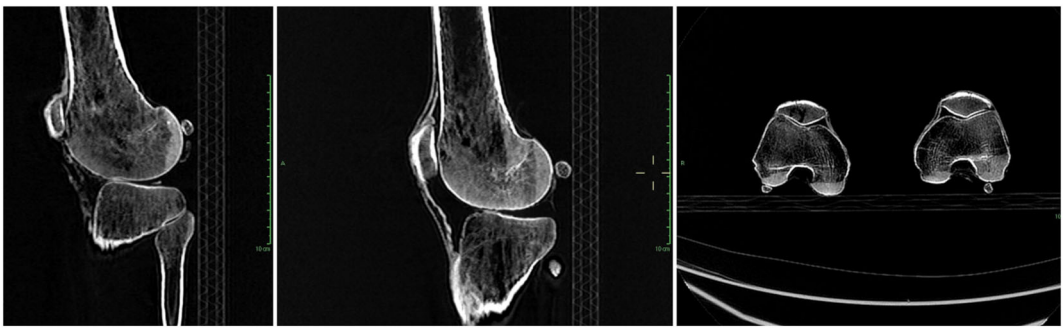

FIGURE 2 Computed tomography (CT) multiplanar reconstructions of the knees (from left to right: Coronal section of right and left knee; transverse sections of right and left distal femoral epiphyses)

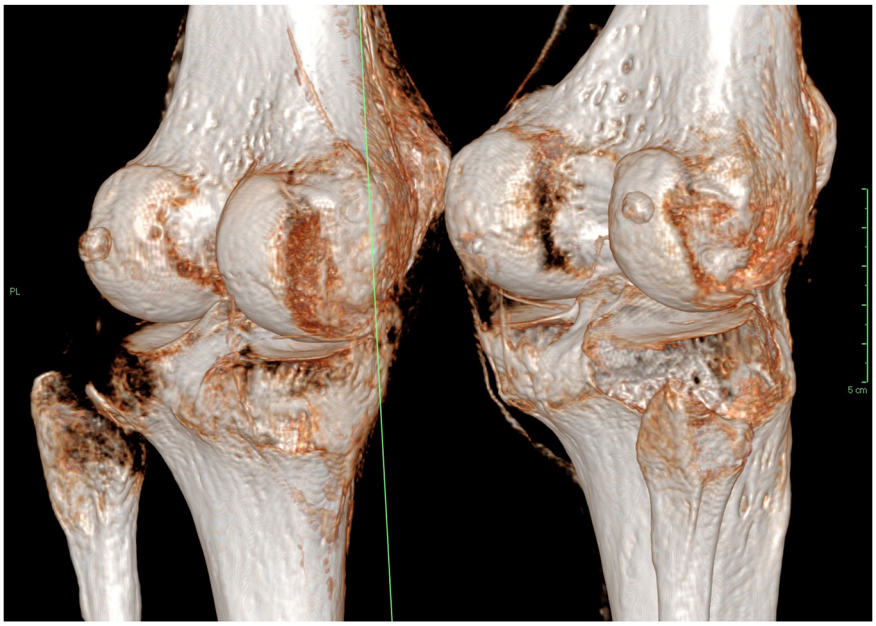

FIGURE 3 3D rendering of the knees viewed from popliteal aspects (left knee on the left). Evidence of fabellae behind both lateral femoral condyles

FIGURE 4 Macroscopic appearance of both popliteal regions with fabellae projecting in the posterosuperior aspect of the lateral femoral condyles (left knee on the left)

5 | DISCUSSION

The presence of fabella is due to a combination of genetic and environmental factors (Berthaume et al., 2019). The occurrence of a cartilaginous fabella, even though less frequent than its bony counterpart, suggests that this sesamoid bone is formed by endochondral ossification, most probably under compressive load on the lateral gastrocnemius tendon (Dalip et al., 2018; Hou et al., 2019). The typical kneeling, squatting and tailor position assumed by Asians can give persistent pressure of the tendon against the posterior aspect of the condyle, promoting fabella development and ossification (Hou et al., 2019). Also, the positive correlation of fabella prevalence with the age of the subjects and knee osteoarthritis may be explained by repeated mechanical stress in the district (Hou et al., 2019).

The prevalence of fabellae greatly varies among countries and ethnicities, with reported rates ranging from 3% to 87% (Berthaume et al., 2019; Hou et al., 2019). It occurs bilaterally in up to 80% of the cases (Dalip et al., 2018). Fabella is more frequently found in the Asian population, older people and patients with knee osteoarthritis (Berthaume & Bull, 2020; Hou et al., 2019). The maximum diameter of the reported lesions ranges from 4 to 30 mm (Agathangelidis et al., 2016). Unlike other sesamoid bones, the prevalence rate of fabellae has increased over the past hundred years (Berthaume et al., 2019; Berthaume & Bull, 2020). This led to hypothesize that the global increase in human height and weight may have increased human tibial length and muscle mass, leading to a larger moment arm acting on the mechanical stimuli necessary to initiate fabella formation (Berthaume et al., 2019).

Fabella is usually asymptomatic, but if large enough can cause mechanical symptoms, such as snapping knee (Agathangelidis et al., 2016). In rare cases, fabella may also harbour pathologies, such as chondromalacia, osteoarthritis, dislocation and fracture, resulting in fabella pain syndrome, common fibular nerve palsy, or popliteal artery

entrapment syndrome (PAES), which influences the common fibular nerve or popliteal artery (Dalip et al., 2018; Hou et al., 2019). In Bassand's case, the small dimensions of both fabellae did not justify symptoms, nor the latter were traced in hagiographies. In fact, no significant pathologic finding was highlighted on the expense of the fabellae.

In conclusion, we reported the first description of a bilateral fabella, diagnosed in a mummified body dating back to the 15th century and belonged to an elderly, non-Asian subject. This case represents a unique description of fabella in ancient human remains, as well as the most ancient report of this sesamoid bone in history, dating back to the 15th century a condition retrospectively investigated since only 100 years ago (Berthaume & Bull, 2020). Moreover, it confirms the importance of both X-ray examination and CT scanning as an essential diagnostic tool and capable of further investigating ancient human remains (Lynnerup & Rühli, 2015; Petrella et al., 2016). Even basic radiology methods when applied to a single subject may yield huge amounts of information about morphological anomalies (Ventura, Fornaciari, et al., 2020; Ventura, Gaeta, et al., 2020).

CONFLICT OF INTEREST

The authors have no conflict of interest to declare.

AUTHOR CONTRIBUTIONS

LV and FB acquired the data and analysed the data. LV drafted the manuscript with input from FB. FB, AB and CM critically revised the manuscript. All authors gave final approval for pubblication.

DATA AVAILABILITY STATEMENT

Data sharing not applicable to this article, as no datasets were generated or analysed during the current study.

ORCID

Luca Ventura https://orcid.org/0000-0002-1526-3941
Federico Bruno https://orcid.org/0000-0002-1444-2585
Antonio Barile https://orcid.org/0000-0003-0253-3583
Carlo Masciocchi https://orcid.org/0000-0001-5713-0875

REFERENCES

Agathangelidis, F., Vampertzis, T., Gkouliopoulou, E., & Papastergiou, S. (2016). Symptomatic enlarged fabella. *BML Case Reports*. https://doi.org/10.1136/bcr-2016-218085

Berthaume, A., & Bull, A. M. J. (2020). Human biological variation in sesamoid bone prevalence: The curious case of the fabella. *Journal of Anatomy*, *236*, 228–242. https://doi.org/10.1111/joa.13091

Berthaume, A., Di Federico, E., & Bull, A. M. J. (2019). Fabella prevalence rate increases over 150 years, and rates of other sesamoid bones remains constant: A systematic review. *Journal of Anatomy*, *235*, 67–79. https://doi.org/10.1111/joa.12994

Dalip, D., Iwanaga, J., Oskouian, R. J., & Tubbs, R. S. (2018). A comprehensive review of the fabella bone. *Cureus*, *10*, e2736. https://doi.org/10.7759/cureus.2736

Hou, W., Xu, L., Wang, J., Wang, B., Liu, L., Xu, K., Cai, Y., Guo, H., & Xu, P. (2019). Fabellar prevalence, degeneration and association with knee osteoarthritis in the Chinese population. *Nature Sci Rep*, *9*, 13046. https://doi.org/10.1038/s41598-019-49174-1

Lovejoy, C. O. (1985). Dental wear in the Libben population: Its functional pattern and role in the determination of adult skeletal age at death. *American Journal of Physical Anthropology*, *68*, 47–56. https://doi.org/10.1002/ajpa.1330680105

Lynnerup, N., & Rühli, F. (2015). Short review: The use of conventional X-rays in mummy studies. *The Anatomical Record*, *298*, 1085–1087. https://doi.org/10.1002/ar.23147

Meindl, R. S., & Lovejoy, C. O. (1985). Ectocranial suture closure: A revised method for the determination of skeletal age at death based on the lateral-anterior sutures. *Am J Phys Anthropol*, *68*, 57–66. https://doi.org/10.1002/ajpa.1330680106

Petrella, E., Piciucchi, S., Feletti, F., Barone, D., Piraccini, A., Minghetti, C., Gruppioni, G., Poletti, V., Bertocco, M., & Traversari, M. (2016). CT scan of thirteen natural mummies dating back to the XVI-XVIII centuries: An emerging tool to investigate living conditions and diseases in history. *PLoS ONE*, *11*, e0154349. https://doi.org/10.1371/journal.pone.0154349

Shaw, R. L. J. (2018). *The Celestine monks of France, c. 1350-1450: Observant reform in an age of schism, council and war*. Amsterdam: University Press.

Ventura, L., Fornaciari, G., Calabrese, A., Arrizza, L., & Fornaciari, A. (2020). Paleopathology of a 19th century mummy of a nobleman from Popoli, Central Italy. *Med Historica*, *4*, 29–34.

Ventura, L., & Gaeta, R. (2020). The facial skin eruption in the mummy of the Blessed Jean Bassand (c. 1360-1445). *Medical Hypotheses*, *144*, 110003. https://doi.org/10.1016/j.mehy.2020.110003

Ventura, L., Gaeta, R., Picchioni, L., & Ioannucci, M. (2019). Facial skin eruption in the mummy of the Blessed Jean Bassand (c. 1360-1445). A report from the preliminary survey. *Paleopathol Newslett*, *185*, 29–32.

Ventura, L., Gaeta, R., Zampa, V., Aringhieri, G., Fornaciari, G., Di Lernia, S., Tafuri, M. A., Manzi, G., & Franchi, A. (2020). Enostosis, hyperostosis corticalis generalisata and possible overlap syndrome in a 7000 years old mummy from Libya. *European Journal of Radiology*, *130*, 109183. https://doi.org/10.1016/j.ejrad.2020.109183

How to cite this article: Ventura, L., Bruno, F., Barile, A., & Masciocchi, C. (2021). Bilateral fabella in the mummy of the Blessed Jean Bassand (c. 1360–1445): A unique description in ancient human remains. *International Journal of Osteoarchaeology*, 1–4. https://doi.org/10.1002/oa.3019