



Osimertinib as induction therapy for oligometastatic non-small cell lung cancer with EGFR mutation: a case report

Han Wu¹, Junwei Ning¹, Ziming Li¹, Duilio Divisi², Antonio Rossi³, Alessio Cortellini⁴, Sang-Won Um⁵, Yusuke Okuma⁶, Chiara Lazzari⁷, Qingquan Luo¹, Tianxiang Chen¹

¹Shanghai Lung Cancer Center, Shanghai Chest Hospital, Shanghai Jiao Tong University School of Medicine, Shanghai, China; ²Department of Life, Health and Environmental Sciences, University of L'Aquila, Thoracic Surgery Unit, "Giuseppe Mazzini" Hospital of Teramo, Teramo, Italy; ³Oncology Center of Excellence, Therapeutic Science & Strategy Unit, IQVIA, Milan, Italy; ⁴Department of Surgery and Cancer, Imperial College London, London, UK; ⁵Division of Pulmonary and Critical Care Medicine, Department of Medicine, Samsung Medical Center, Sungkyunkwan University School of Medicine, Seoul, Korea; ⁶Department of Thoracic Oncology, National Cancer Center Hospital, Tokyo, Japan; ⁷Candiolo Cancer Institute, FPO-IRCCS, Candiolo, Italy

Correspondence to: Tianxiang Chen; Qingquan Luo. Shanghai Lung Cancer Center, Shanghai Chest Hospital, Shanghai Jiao Tong University School of Medicine, 241 Huai Hai Road, Shanghai 200030, China. Email: txchen@shsmu.edu.cn; luqingquan@hotmail.com.

Background: The role of surgery in combined modality therapy for selected stage IV oligometastatic (OM) non-small cell lung cancer (NSCLC) is still controversial. Tyrosine kinase inhibitors (TKIs) targeting epidermal growth factor receptor (EGFR) significantly improved the survival in adjuvant therapy in metastatic NSCLC but has rare evidence in inductive setting. This is the first case report about uniportal video-assisted thoracic surgery after induction therapy of TKI for OM-NSCLC.

Case Description: A 50-year-old Chinese woman presented to hospital with headache and blurred vision and was diagnosed with an intracranial tumor. The craniotomy confirmed the metastasis from primary lung cancer. Positron emission tomography/computed tomography (PET/CT) showed the mass located in the left upper lobe and left hilar lymph node involvement. Next-generation sequencing found an EGFR mutation (exon 21 p.L858R missense), and osimertinib, a third-generation TKI, was used 80 mg per day as the induction therapy due to the EGFR mutation detected from the metastatic tumor. A favorable treatment response was observed of the lung tumor with lymph node regression, followed by uniportal thoracoscopic left upper lobectomy and systematic lymphadenectomy. The postoperative pathology evaluated both the lung lesion and lymph nodes and confirmed the OM status of this patient. No complications were observed and postoperative osimertinib 80 mg per day continued.

Conclusions: Our case suggests that the role of surgery should be appropriately reevaluated for EGFR-mutated OM-NSCLC with the emerging development of EGFR-TKI.

Keywords: Non-small cell lung cancer (NSCLC); induction therapy; surgery; oligometastatic (OM); case report

Submitted Jan 21, 2022. Accepted for publication Apr 22, 2022.

doi: 10.21037/tlcr-22-251

View this article at: <https://dx.doi.org/10.21037/tlcr-22-251>

Introduction

Lung cancer is the second most common type of cancer worldwide in both genders and one of the leading causes of cancer-related death (1). Surgery is the standard treatment for early-stage non-small cell lung cancer (NSCLC), whereas metastatic disease is primarily managed with systemic

treatments, like chemotherapy, immunotherapy, and targeted therapies. The oligometastatic (OM) state of malignant disease was first proposed by Hellman and Weichselbaum in 1995, representing an intermediate state between locoregional and metastatic diseases (2). Unlike regular late-stage disease, OM cancer may potentially benefit from local ablative therapy, including surgery, radiotherapy, or radiofrequency ablation

(3-5). Currently, OM-NSCLC still has no conclusive definition, but a maximum of five metastases and the involvement of three organs is widely accepted (6,7).

Local ablative therapies combined with systemic therapies have also been shown as safe and efficacious in OM-NSCLC patients. Previous research evaluating the effects of local ablative therapies on OM-NSCLC has focused more on radiotherapy than surgery. The specific role of surgery remains controversial, and there are many unresolved questions, such as long-term outcomes and patient selection. There is currently insufficient high-quality evidence to determine whether surgery or radiotherapy is the superior choice as a classical local ablative therapy option for OM-NSCLC. However, surgery has an unparalleled advantage over radiotherapy in the complete pathological evaluation of the tumor and lymph nodes. Most published evidence about the combination of systemic treatment and local ablative therapies was generated from patients receiving chemotherapy (8-10). With the development of targeted therapy in recent years, the role of surgery in OM-NSCLC patients may need to be further investigated. Here, we present the first case report of OM-NSCLC with epidermal growth factor receptor (EGFR) mutations who received osimertinib, a third-generation irreversible tyrosine kinase inhibitor (TKI), as induction therapy and underwent uniportal video-assisted thoracic surgery. We present the following article in accordance with the CARE reporting checklist (available at <https://tclr.amegroups.com/article/view/10.21037/tclr-22-251/rc>).

Case presentation

A 50-year-old Chinese woman with no significant past medical history presented to Shanghai Gamma Knife Hospital with headache and blurred vision in May 2021. She also complained of nausea and weakness in the right limbs. The magnetic resonance imaging (MRI) of the brain showed a 55-mm diameter mass located in the occipital lobe. The patient underwent craniotomy to ease her neurological symptoms. The pathology report confirmed that the intracranial tumor was metastasized from primary lung cancer. Next-generation sequencing found an EGFR mutation (exon 21 p.L858R missense), but no *ALK*, *ROS1*, *BRAF*, *MET*, *RET*, or other gene mutations were detected. The PD-L1 protein expression level of the brain metastases assessed by immunohistochemistry (22C3 antibody) showed that TPS was <1% and CPS was <1. The tumor mutation burden (TMB) was 0.52 mut/Mb <10 mut/Mb,

with a microsatellite stability (MSS) state, which all indicated the patient was not sensitive to PD-1/PD-L1 inhibitors. The positron emission tomography/computed tomography (PET/CT) revealed a left upper lung mass 30 mm × 21 mm in size, which was fluorodeoxyglucose (FDG)-avid (SUVmax 12.6) with left hilar lymph node involvement (SUVmax 5.6) measuring approximately 14 mm in the largest dimension. After that, this patient came to Shanghai Chest Hospital for further treatment. The patient was diagnosed with stage IVA (cT1cN1M1b) with EGFR mutation. Since the metastatic intracranial lesion was completely removed by surgery, induction therapy of osimertinib 80 mg daily for a total of 4 weeks was eventually approved by the multidisciplinary team, which was tolerated well without adverse effects. In July 2021, PET/CT performed after osimertinib treatment showed a favorable treatment response, with a radiological regression in the left upper lobe lesion from 30 mm × 21 mm to 18 mm × 12 mm, and a decrease in FDG activity from SUVmax 12.6 to 6.6. The FDG active left hilar lymphadenopathy also disappeared (*Figure 1*). The induction therapy downstaged the patient's N1 status to N0 status, so the resection of the primary lung tumor was approved after multidisciplinary discussion. Informed consent was obtained from the patient, and she received 3-dimensional uniportal video-assisted thoracoscopic left upper lobectomy and systematic lymphadenectomy (*Video 1*). Postsurgical pathology showed microscopic foci of residual invasive adenocarcinoma (50% acinar pattern-predominant adenocarcinoma with 40% complex glandular component and 10% solid pattern-predominant adenocarcinoma), 0/11 lymph nodes with tumor involvement, and no lymphovascular or visceral pleural invasion. The postoperative pathological stage was ypT1N0M1b, which confirmed the OM status of this patient. The thoracic drainage tube was withdrawn 3 days after surgery, and the patient was discharged 4 days after surgery. No complications were observed during hospitalization. Postoperative osimertinib 80 mg per day continued, and the chest CT, brain MRI, and blood test were all negative six months after surgery. The timeline of all treatments is listed in *Figure 1*. All procedures performed in this study were in accordance with the ethical standards of the institutional and/or national research committee(s) and with the Declaration of Helsinki (as revised in 2013). Written informed consent was obtained from the patient for publication of this case report and accompanying images. A copy of the written consent is available for review by the editorial office of this journal.

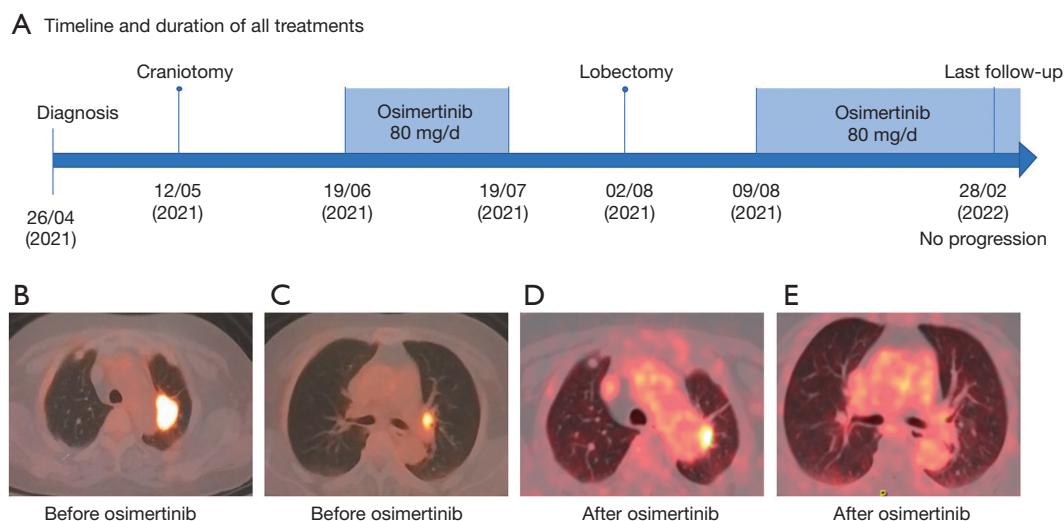
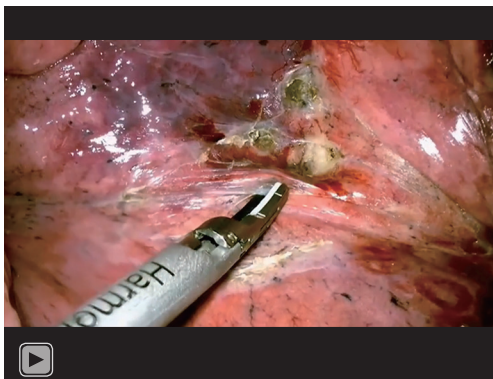


Figure 1 Timeline of all treatments, disease status measured by PET/CT before and after osimertinib therapy. (A) Timeline and duration of all treatments; (B) left upper lobe pulmonary nodule measuring 30 mm × 21 mm with maximum SUVmax of 12.6 before induction therapy; (C) left hilar lymph node measuring up to 14 mm in the long axis with SUVmax of 5.6 before induction therapy; (D) left upper lobe pulmonary nodule measuring 18 mm × 12 mm with maximum SUVmax of 6.6 after induction therapy; (E) left hilar lymph node disappeared after induction therapy. PET/CT, positron emission tomography/computed tomography. SUV, standard uptake value.



Video 1 Surgical procedure of uniportal VATS left upper lobectomy after osimertinib induction for an oligometastatic NSCLC patient. VATS, video-assisted thoracoscopic surgery; NSCLC, non-small cell lung cancer.

International Multidisciplinary Team (iMDT) discussion

Discussion among physicians from Shanghai Chest Hospital

We conducted multidisciplinary consultation for this case. After craniotomy, our patient received osimertinib as induction therapy prior to pulmonary surgery. Imaging

obtained after 4 weeks of osimertinib demonstrated a favorable partial response which allowed for complete resection of the pulmonary lesion. Multiple questions remain about the use of EGFR TKIs combined with surgery. The optimal timing for induction therapy and surgery remains unclear. And maintenance therapy after surgery for patients who have demonstrated a favorable response to induction therapy should also be considered.

Department of Medical Oncology

OM-NSCLC is supposed to be an intermediate state of stage IV NSCLC, which may potentially benefit from local ablative therapies (3-5). Historically, chemotherapy has mostly been used for stage IV NSCLC, but there are concerns about its ability to cross the blood-brain barrier, which possibly explains the inferior response rates of 20–40% (11,12). However, current work with small molecule inhibitors reveals that these agents may be able to cross the blood-brain barrier and control intracranial disease.

The ADJUVANT and SELECT trials have demonstrated improved disease-free survival (DFS) after EGFR-TKI in the adjuvant setting with gefitinib and erlotinib, respectively (13,14). Osimertinib, a third-generation irreversible TKI, has demonstrated superiority in untreated EGFR-mutated advanced NSCLC compared

to first-generation TKIs (15). Most recently, the ADAURA phase III clinical trial demonstrated a significantly improved 2-year DFS of 90% in favor of osimertinib versus 44% for placebo in the adjuvant setting for stage II, or IIIA NSCLC (16). An interim analysis of the NEOS study indicated neoadjuvant osimertinib was an effective and feasible treatment in patients with resectable stage II–IIIB EGFR-mutated NSCLC (17). Osimertinib is expected to be effective in patients with CNS metastasis because it has displayed greater penetration into the brain than earlier generation TKIs in a preclinical model (18).

Department of Surgical Oncology

The use of TKIs combined with local ablative therapies in OM-NSCLC is rarely reported. Existing research has focused more on radiotherapy, and the role of surgery is controversial. The SINDAS study, a randomized controlled trial, investigated upfront concurrent first-generation TKI treatment with and without stereotactic ablative radiotherapy (SABR) for synchronous EGFR-mutated OM-NSCLC, followed by maintenance TKI. The data indicated that SABR plus TKI was associated with an improvement in overall survival (OS) and progression-free survival (PFS) compared to TKI alone (19). For patients with OM CNS metastases amenable to resection, surgery was considered the best initial therapeutic strategy. For most patients, craniotomy is usually performed before surgery for the primary lung tumor (20).

As a result, the published evidence indicated that the optimal strategy to cure OM-NSCLC with EGFR mutations is to initiate EGFR-TKIs. A comprehensive assessment is necessary to ensure disease control before starting local ablative therapies. EGFR-TKI therapy after all lesions are treated with local ablative therapies is controversial and needs to be confirmed by randomized trials. To date, we can only refer to trials of adjuvant treatment in EGFR-mutated NSCLC (13,14,16).

So, in this case report, we observed a favorable treatment response of the lung tumor and lymph node regression after osimertinib treatment in OM-NSCLC, followed by uniportal video-assisted thoracic surgery as a feasible local treatment. However, there are some limitations in our study. Firstly, due to economic factors, the patient only underwent genetic testing for the metastatic brain lesion, not for primary lung lesion. Secondly, the follow-up time is still very short, and further follow-up of the patient is required. Thirdly, due to the limitation of the case report itself, more evidence from retrospective or randomized

studies are needed to reach definitive conclusions.

In conclusion, this case suggests that the role of surgery should be reevaluated after induction therapy of TKIs for patients with EGFR-mutated OM-NSCLC. In the era of targeted and immune therapy, radical surgery as an effective local treatment may achieve a better outcome for OM-NSCLC.

Several issues regarding the diagnosis and treatment of this patient were further discussed as follows

What kind of local treatment should we choose for such an OM patient? Surgery or radiotherapy? What are the advantages and disadvantages of these two options?

Duilio Divisi: N-stage and tumor size are the most important factors to proceed of a radical treatment in an OM patient. In fact, the primary tumor control without N2 is the fundamental clinical condition to indicate an aggressive approach. Then the preoperative study of the mediastinum through a cytohistological evaluation of the lymph node stations leads the way to follow. In this regard, EBUS/TBNA-TBNB is an easy, safe, fast and well-tolerated procedure with the diagnostic performance comparable to that of the most invasive techniques. Metastasectomy is the advisable strategy in order to achieve local R0 in an advanced cancer, followed by NSCLC resection with associated lymphadenectomy; the surgical choice is questionable or contraindicated in case of two or multiple metastases respectively. Radiotherapy, as fractionated whole-brain irradiation therapy (WBRT) or stereotactic radiosurgery (SRS) is required in a patient not suitable for invasive or minimally invasive surgery. Although outcomes about local tumor control, quality of life, morbidity (neurocognitive function preservation, toxicity) and mortality are still extremely inhomogeneous, SRS appears to be preferable to WBRT (21).

Antonio Rossi: Local treatments for OM brain lesions mainly include surgical resection, radiotherapy, including whole brain, SRS, or both, or a combination of surgery and radiotherapy. Regardless of the therapeutic approach used, minimal invasiveness is crucial. With the recent improvements in surgical techniques as well as in perioperative management, surgery has become safer and less invasive. On the other hand, recent radiotherapy technological advances have allowed for the delivery of very high, potentially ablative, doses of radiotherapy in much shorter time periods compared to conventional radiation and with minimal associated toxicity. Local control appears

to be equivalent, whether by means of surgical resection or radiotherapy. However, surgery should be performed on patients whose stable primary lesions and metastases are potentially completely resectable. Metastasectomy can be performed only when R0 resection is obtainable, also enabling histological analysis of the resected tissue, whereas radiotherapy is better established prospectively and, as a non-invasive technique, should have a low rate of early side effects. In such an OM patient, the choice of surgery was considered the most appropriate to rapidly reach a control of symptoms and to have enough tissue for the appropriate diagnosis. Overall, the options of local treatment should be chosen by an interdisciplinary tumor board individually for suitable patients.

Alessio Cortellini: Surgical resection represents the recommended first approach to a newly diagnosed symptomatic single brain metastases, especially with large lesions, with diameters greater than 2 cm, like the presented case, as targeted radiation techniques most likely would not have a radical effect (22). A brain MRI should always be performed, to exclude the presence of other lesions and the procedure should be deemed as safe and doable. The advantages of the surgical approach are the radical intent and the subsequent tissue availability. Targeted radiation therapies (e.g., SRS), are recommended as front-like approach with radical intent in case of multiple brain metastases or single metastases of small diameter/with difficult surgical approach (23).

Sang-Won Um: Surgery has advantage over radiotherapy in the complete removal and pathological evaluation of the primary tumor and metastatic lesions. For the primary lesion, I will choose surgery if the patient's condition permits and N2/N3 nodal metastasis is excluded by minimally invasive mediastinal staging such as endosonography. For the metastatic brain lesions, surgery or SRS could be used considering the characteristics of lesions (size and number) and neurologic symptoms or signs. I will choose radiotherapy for metastatic bone lesions for local control and pain relief.

Yusuke Okuma: Surgical removable of solitary brain metastasis is a standard of care for this patient because it was symptomatic and >3 cm in size. I would not recommend surgical removal for the thoracic lesions in my clinical practice. However, recent progress in the medical technologies in surgery or radiotherapy has shown less invasion procedures and some oncologists may consider curative-intent "local treatment". Also, until a few years ago, I had never recommended local treatment for patients

with OM lesion(s). However, based on the recent serial successes proven in randomized phase 2 studies (9,24,25), a consensus report from ESTRO and EORTC (6,26), and Japan Lung Cancer Society Guidelines' recommendation (27) update, I cannot help suggesting patients to local treatment by surgical removal or ablation therapy for OM lesions of up to five sites within three organs (6). At the same time, the consideration for local treatment for OM lesions is still optional because of the limited evidence without any confirmative studies. As for patients with OM NSCLC harboring genetic alterations treated with targeted therapy, I do need to consider thoroughly in looking for the right patients who benefit from local therapy compared to those who are treated with chemotherapy. The results of the randomized phase 2 trial have shown us that local therapy for OM lesions has prolonged PFS by means of median survival time (24,28), but there is little meaning for cure based on the 2- or 3-year landmark (28). In this content, the patients will continue to be treated with less toxic targeted therapy, for example, osimertinib for EGFR mutation or alectinib for ALK-rearranged NSCLC, and it will be biologically plausible on the basis of tumor heterogeneity. I am guessing immune checkpoint inhibitors will extrapolate the existing pieces of evidence (29). As for the disadvantages, we need to consider the late phase toxicities induced by radiotherapy (9) or invasive perioperative risks, resulting in negative consequences such as being unable to continue to later lines of pharmacotherapy.

Chiara Lazzari: Despite the high percentage of objective response rate (ORR), and the prolongation of progression free survival (PFS) and OS in patients receiving targeted agents, due to intratumoral heterogeneity, complete responses are rarely observed, and the development of acquired resistance mechanisms inevitably emerge, therefore resulting into tumor progression. EGFR mutated NSCLC are heterogeneous tumors. Co-occurring mutations in TP53, PIK3CA, catenin beta-1 (CTNNB1) and RB1 (30) have been observed. Local treatments are used to target intratumor heterogeneity, with the aim to eliminate the quiescent surviving cells, not responding to treatment, and responsible for progression. No clinical trial has been designed yet to compare the efficacy of surgery over radiotherapy, and currently there are evidences from literature suggesting the impact of local strategies, but with no clear superiority of one over the other. In a phase II clinical trial, 49 patients with oligo-metastatic NSCLC (≤ 3 metastatic sites), naive from previous therapies, stratified by the number of metastatic lesions, the presence of

brain metastases, the intrathoracic nodal status, and the presence of EGFR activating mutations or the EML4-ALK rearrangement, were randomized between surgery and radiotherapy or maintenance treatment, following three months of systemic therapy, selected according to the molecular status (crizotinib in ALK positive patients, EGFR-TKIs in EGFR mutant patients, and platinum doublets in wild type population). The use of a local strategy significantly prolonged PFS (14.2 *vs.* 4.4 months, $P=0.022$) and OS (41.2 *vs.* 17.0 months, $P=0.017$) (31). Considering there is not a clear advantage in terms of efficacy of surgery over radiotherapy, co-morbidities, the patient's ECOG PS, the age, the number of metastatic sites, the involvement of mediastinal lymph nodes and the location of metastases should be considered. In younger patients, with no mediastinal nodal involvement, and metastases in a single organ, surgery should be preferred, while radiotherapy should be the option in the other cases. Radical surgery could be associated with a higher probability of eradicating quiescent tumor cells, therefore prolonging survival. Moreover, the pathological evaluation of the tumor and lymph nodes allows to characterize the percentage of pathologic response following induction therapy, and to better define patient's prognosis. However, further analyses are warranted to determine which is the best local treatment strategy.

What kind of induction therapy should we choose for such an OM patient? Chemotherapy or targeted therapy?

Duilio Divisi: The choice of induction therapy is now linked to the knowledge of the biological features of cancer, having not only a predictive but also a prognostic role. In patients with target alterations (sensitizing mutations of the EGFR gene, translocation of the ALK gene), the first-line use of TKIs (osimertinib, alectinib, brigatinib) showed a benefit in terms of PFS, OS, response rate (RR) and better tolerability than chemotherapy and chemoimmunotherapy. It is widely demonstrated in literature (15,32) that the use of the latest generation TKIs with activity on the central nervous system (osimertinib, alectinib, ceritinib) displays in the presence of oncogenic drivers (EGFR, ALK): (I) the reduction of the incidence of brain metastases; (II) the local control of the disease in patients who develop brain metastases, delaying radiotherapy as much as possible. Conversely, in the absence of target alterations, chemoimmunotherapy or immunotherapy based on PD-L1 expression levels, histology, performance status and comorbidities are the

standard treatment. For the above, the best induction therapy can be considered that with osimertinib in the patient under examination.

Antonio Rossi: Induction therapy has the intent to eradicate nodal and micrometastatic disease, also achieving a shrinking of tumor volume and burden to reach the surgery, and allowing assessing the treatment response and treatment-induced changes in tumor biology. This derived information may guide the decision on the further treatment steps. Surgery after neoadjuvant treatment may be more challenging than the upfront one because it seems to be correlated with a higher risk of post-operative course. There is a limited experience with neoadjuvant administration of EGFR-TKIs indicating that their short-term therapy provided a feasible treatment modality for patients with resectable or potentially resectable EGFR-mutant NSCLC. It is well known that EGFR-TKIs showed a significantly higher response rate and safety than chemotherapy in metastatic NSCLC harboring EGFR sensitizing mutations, and osimertinib showed better outcomes than first-generation EGFR-TKIs. In such an OM patient, osimertinib was administered due to the presence of a sensitizing EGFR gene mutation detected from the resected brain lesion. The choice of osimertinib led to the lung and lymph node regression followed by the surgical radical resection that might further change the natural history of the disease also considering that, after an initial activity lasting around 10–14 months, a disease progression was reported in the majority of metastatic NSCLC patients, with the mechanisms of resistance that may vary.

Alessio Cortellini: Being a stage IV patient, the medical treatment algorithm for this patient correctly followed the existing recommendations for patients with metastatic disease. Therefore, first-line osimertinib was the most appropriate choice.

Sang-Won Um: If the tumor harbors sensitizing EGFR mutations or ALK rearrangements, targeted therapy seems to be a good option. However, previous studies about neoadjuvant EGFR-TKIs or ALK-TKIs were usually small sample sizes and single-arm studies (33,34). More data are needed to elucidate the exact role of EGFR-TKIs or ALK-TKIs in the neoadjuvant setting.

Yusuke Okuma: On the basis of the existing pieces of evidence, we need to choose the targeted therapy or chemotherapy depending on the genetic status. But it will be okay to treat them with local treatment alone if patients with OM lesions had not been on any pharmacotherapy if I

consider the induction pharmacotherapy to the patients. In my opinion, I will regard important as higher response rates based on the existing evidences at first to facilitate surgical removal as well as tolerability.

What is the best time interval between induction therapy and surgery?

Duilio Divisi: Currently, there are no data on the best time interval between induction therapy and surgery in OM disease of lung cancer. However, it may be reasonable to consider 8 weeks treatment approximately followed by instrumental re-evaluation (indirect data from the NeoADAURA study in the neoadjuvant setting) (35).

Antonio Rossi: Following neoadjuvant treatment, the patient is assessed for eligibility for surgery. It is generally agreed that if the patient is eligible, surgery should be performed up to a maximum of 12 weeks following the start of neoadjuvant treatment. The few experiences with neoadjuvant administration of EGFR-TKIs report a time interval from drug discontinuation to surgery of around one week.

Alessio Cortellini: There is no evidence to suggest this, as an induction approach was historically restricted to non-metastatic patients. Good common sense would suggest that the correct timing would be the moment of best response, between 1 and 2 months.

Sang-Won Um: Although we have insufficient data for the optimal duration of induction therapy, a reasonable time interval should be guaranteed for the tumor shrinkage before surgery. Several studies adopted different time periods for induction therapy using EGFR-TKIs. In the ongoing NeoADAURA trial (NCT04351555) which evaluates neoadjuvant osimertinib alone, osimertinib plus chemotherapy (platinum + pemetrexed), or chemotherapy alone in non-squamous stage II-IIIb N2 NSCLC with confirmed EGFR mutations (exon 19 del or L858R), the duration of neoadjuvant osimertinib is >9 weeks (35). However, in EMERGING-CTON 1103 trial (NCT01407822), the duration of neoadjuvant erlotinib was 6 weeks in stage III-N2 NSCLC with EGFR mutations (36). Interestingly, Chen *et al* reported that 29 patients with advanced EGFR-mutant lung adenocarcinomas underwent salvage lung resections after EGFR-TKIs with a median treatment duration of 5 months (37). For the optimal duration of induction therapy using osimertinib, we have to wait for the results for NeoADAURA and NEOS trials.

Yusuke Okuma: The optimal treatment interval with induction chemotherapy still remains unclear, but we usually adapt it according to the package insert. I recognize

the appropriate intervals are 1–4 weeks for chemotherapy, a week for targeted therapy, and 4 weeks for anti-angiogenic agents based on the treatment cycle or pharmacokinetics/pharmacodynamics.

Chiara Lazzari: There are not clear evidences about the optimum duration of induction therapy. However, considering that, especially in molecularly selected patients receiving targeted therapy, the best percentage of objective response is observed within the first four months from the beginning of treatment, this interval should be considered in order to perform surgery at the maximum of tumor response.

What is the best adjuvant therapy for this patient after resection of all lesions? Targeted therapy alone or combined with adjuvant chemotherapy?

Duilio Divisi: Starting from the data from the ADAURA study (38), concerning radically operated NSCLC patients in stage IB-IIIa and transferring them to the OM disease, the best adjuvant therapy for this patient after resection of all lesions is the targeted therapy with osimertinib. The association with adjuvant chemotherapy should be evaluated based on the general clinical conditions, comorbidities and postoperative recovery.

Antonio Rossi: There is no consensus on what should be the best adjuvant approach after neoadjuvant EGFR-TKI followed by surgery in patients affected by OM NSCLC harboring EGFR sensitizing mutations. The treatment strategy should be evaluated case by case by a multidisciplinary team. In this specific case report, the baseline OM disease of the patient was considered as an advanced disease and the multidisciplinary team decision was to continue osimertinib alone after thoracic surgery. This is shareable also in view of the delay of the chemotherapy administration and the effective treatment of adjuvant osimertinib with or without previous adjuvant chemotherapy.

Alessio Cortellini: There is no evidence to suggest this. The ADAURA trial enrolled patients regardless of the receipt of prior adjuvant chemotherapy, and confirmed the beneficial effect of adjuvant osimertinib in both groups (39). However, the case presented was a stage IV upfront, therefore I would have recommended targeted therapy alone.

Sang-Won Um: For this case which harbors EGFR L858R mutation, I will choose to use adjuvant osimertinib alone based on ADAURA trial (38). ADAURA trial showed that disease-free survival was significantly longer among those who received osimertinib than among those who received a placebo in stage IB to IIIa disease. Currently, there is insufficient evidence to support the use of adjuvant

targeted therapy plus chemotherapy. However, the role of adjuvant osimertinib ± chemotherapy is evaluated in ongoing NeoADAURA trial (35).

Yusuke Okuma: At this time, I stand to recommend cisplatin-based chemotherapy to the patients with completely resected NSCLC regardless of EGFR mutation status (40). I believe that molecular targeted agents have not shown enough evidence to be used as curative-related endpoints at this time. Of course, I understand that adjuvant osimertinib treatment for three years confirmed survival benefits from the ADAURA study (38). I will suggest the patients with completely resected NSCLC with Stage IIA-IIIb be treated with Osimertinib to emphasize the survival benefit, but at this point, I cannot confirm that it will impact the patients in a radical way, until the results of OS at five years is presented from the ADAURA study.

Chiara Lazzari: There is no advantage of adding adjuvant chemotherapy to targeted therapy in a patient carrying EGFR activating mutation. The risk could be the onset of toxicity with no impact in terms of prolongation of survival. The maintenance with targeted therapy represents an efficient and safe strategy. Unfortunately, despite the good response observed and the radical surgery, acquired resistance mechanisms might emerge in the course of treatment. An option could be to molecularly characterize the tissue collected at the time of surgery with next generation sequencing (NGS), in order to confirm the presence of EGFR mutation or identify secondary resistance mutations within the tyrosine kinase domain of the EGFR gene, or molecular alterations in other genes. In case of these findings, platinum doublet chemotherapy for four cycles could be considered before maintenance with osimertinib.

Should whole-brain radiotherapy be performed after resection of intracranial metastatic tumor?

Duilio Divisi: Historically it has been shown (41) that, in patients with single brain metastasis undergoing surgical resection, whole-brain radiotherapy (WBRT) reduces the risk of recurrence at the surgical site and elsewhere in the brain, as well as prevents the risk of death from brain causes. To date, there is no evidence that adjuvant WBRT increases survival compared to surgery alone, while more evidence has been produced over the years on the risk of radio-induced neurotoxicity (42). In order to improve local control, it is current practice to use SRS or multi-fraction stereotactic radiosurgery (MF-SRS) which, compared to adjuvant WBRT, are characterized by similar OS rates, but lower chances of cognitive impairment and higher survival

free from cognitive impairment (43). However, WBRT can be considered in patients who have a postoperative residual disease that is not amenable to further surgical treatment or conformal radiotherapy (44). Anyway, in these clinical situations, the WBRT can be omitted if the NSCLC patient is asymptomatic and shows EGFR mutation or ALK rearrangement susceptible to treatment with drugs that cross the blood-brain barrier.

Antonio Rossi: The brain is one of the most common sites for distant metastasis in NSCLC. The rationale for whole-brain radiotherapy is to eliminate potential brain microscopic disease. This justifies the use of whole-brain radiotherapy application after local therapies such as surgical excision or stereotactic radio-surgery. The application of whole-brain radiotherapy aims to improve local control, decreasing the chances for cerebral recurrence, but without benefit for survival, and may be accompanied by the risk of neurocognitive complications. In such an OM patient the use of osimertinib, which is able to cross the blood-brain barrier controlling the brain metastases also reducing the incidence of new brain lesions, can defer or even withhold the administration of whole-brain radiotherapy.

Alessio Cortellini: The addition of postoperative WBRT was historically considered the standard of care, as it demonstrated its efficacy in reducing the risk of local recurrence to the brain (both surgical site and other sites) in randomized studies (41,45). More recently, randomized trials provided evidence supporting the use of adjuvant SRS to the surgical site, as it is associated with a decreased risk of local recurrence in comparison to observation, and a decreased risk of neurocognitive side effects in comparison to WBRT (23). However, none of this evidence accounted for the role of adjuvant EGFR TKIs. Osimertinib in particular showed a brain C_{max} greater than 16 times fold that of gefitinib, whilst the ADAURA trial confirmed its efficacy as adjuvant treatment (18,38). These findings suggest that adjuvant 3rd generation EGFR TKIs could be an effective and safe strategy for patients with radically resected brain metastases from EGFR positive NSCLC, although prospective control trials are needed to widely promote this approach (46).

Sang-Won Um: I think whole-brain radiotherapy is not necessary since the patient is receiving osimertinib which is a highly CNS penetrating agent. The cognitive impairment by whole-brain radiotherapy will negatively affect the quality of life in the relatively young patient (50 years old).

Yusuke Okuma: I would like to avoid treating with whole-brain radiotherapy as long as I can because of its

neurotoxicities including cognitive disorder at the late-phase onset. Therefore, we always recommend the patients with cyberknife radiotherapy for either postoperative residual lesion showed the inferiority for WBRT (47), of course, based on the advice of a radiation oncologist. In terms of prophylactic cranial irradiation (PCI), no survival benefit is shown in a previous study for Stage III NSCLC (48) and, therefore, I am not going to recommend this patient to perform WBRT.

Chiara Lazzari: A boost of radiotherapy following surgery specifically on the resected metastases should be considered.

Acknowledgments

Funding: This work was supported by the Shanghai Talent Development Fund (No. 2019073), the Shanghai Natural Science Foundation (Grant No. 18ZR1435100), the Shanghai Rising Stars of Medical Talent, Youth Development Program (Specialist Program), and the Morningstar award program for outstanding young scholars of Shanghai Jiao Tong University.

Footnote

Reporting Checklist: The authors have completed the CARE reporting checklist. Available at <https://tcr.amegroups.com/article/view/10.21037/tcr-22-251/rc>

Conflicts of Interest: All authors have completed the ICMJE uniform disclosure form (available at <https://tcr.amegroups.com/article/view/10.21037/tcr-22-251/coif>). AR serves as an unpaid editorial board member of *Translational Lung Cancer Research* from November 2018 to October 2022. AC reports that he has received personal fees from Astrazeneca, Roche, BMS and MSD, also received speakers fees from Astrazeneca, Eisai and Novartis. YO reports receiving grants and personal fee from AbbVie GK, F. Hoffmann-La Roche, Ltd., AstraZeneca K.K., Nippon Boehringer Ingelheim Co., Ltd., Ely Lilly Japan K.K, Chugai Pharmaceutical Co. Ltd., Bristol Meiers Squibb Company, Ono Pharmaceutical Co. Ltd., Pfizer Japan Inc., Taiho Pharmaceutical Co. Ltd., and also serves as an unpaid editorial board member of *Translational Lung Cancer Research* from January 2020 to December 2023. The other authors have no conflicts of interest to declare.

Ethical Statement: The authors are accountable for all

aspects of the work in ensuring that questions related to the accuracy or integrity of any part of the work are appropriately investigated and resolved. All procedures performed in this study were in accordance with the ethical standards of the institutional and/or national research committee(s) and with the Declaration of Helsinki (as revised in 2013). Written informed consent was obtained from the patient for publication of this case report and accompanying images. A copy of the written consent is available for review by the editorial office of this journal.

Open Access Statement: This is an Open Access article distributed in accordance with the Creative Commons Attribution-NonCommercial-NoDerivs 4.0 International License (CC BY-NC-ND 4.0), which permits the non-commercial replication and distribution of the article with the strict proviso that no changes or edits are made and the original work is properly cited (including links to both the formal publication through the relevant DOI and the license). See: <https://creativecommons.org/licenses/by-nc-nd/4.0/>.

References

1. Siegel RL, Miller KD, Jemal A. Cancer statistics, 2020. *CA Cancer J Clin* 2020;70:7-30.
2. Hellman S, Weichselbaum RR. Oligometastases. *J Clin Oncol* 1995;13:8-10.
3. Pfanschmidt J, Dienemann H. Surgical treatment of oligometastatic non-small cell lung cancer. *Lung Cancer* 2010;69:251-8.
4. Siva S, MacManus M, Ball D. Stereotactic radiotherapy for pulmonary oligometastases: a systematic review. *J Thorac Oncol* 2010;5:1091-9.
5. Collaud S, Stahel R, Inci I, et al. Survival of patients treated surgically for synchronous single-organ metastatic NSCLC and advanced pathologic TN stage. *Lung Cancer* 2012;78:234-8.
6. Dingemans AC, Hendriks LEL, Berghmans T, et al. Definition of Synchronous Oligometastatic Non-Small Cell Lung Cancer-A Consensus Report. *J Thorac Oncol* 2019;14:2109-19.
7. Lievens Y, Guckenberger M, Gomez D, et al. Defining oligometastatic disease from a radiation oncology perspective: An ESTRO-ASTRO consensus document. *Radiother Oncol* 2020;148:157-66.
8. Wei Z, Ye X, Yang X, et al. Microwave ablation plus chemotherapy improved progression-free survival of advanced non-small cell lung cancer compared to

- chemotherapy alone. *Med Oncol* 2015;32:464.
9. Palma DA, Olson R, Harrow S, et al. Stereotactic ablative radiotherapy versus standard of care palliative treatment in patients with oligometastatic cancers (SABR-COMET): a randomised, phase 2, open-label trial. *Lancet* 2019;393:2051-8.
 10. Palma DA, Olson R, Harrow S, et al. Stereotactic Ablative Radiotherapy for the Comprehensive Treatment of Oligometastatic Cancers: Long-Term Results of the SABR-COMET Phase II Randomized Trial. *J Clin Oncol* 2020;38:2830-8.
 11. Franciosi V, Cocconi G, Michiara M, et al. Front-line chemotherapy with cisplatin and etoposide for patients with brain metastases from breast carcinoma, nonsmall cell lung carcinoma, or malignant melanoma: a prospective study. *Cancer* 1999;85:1599-605.
 12. Cortes J, Rodriguez J, Aramendia JM, et al. Front-line paclitaxel/cisplatin-based chemotherapy in brain metastases from non-small-cell lung cancer. *Oncology* 2003;64:28-35.
 13. Pennell NA, Neal JW, Chaft JE, et al. SELECT: A Phase II Trial of Adjuvant Erlotinib in Patients With Resected Epidermal Growth Factor Receptor-Mutant Non-Small-Cell Lung Cancer. *J Clin Oncol* 2019;37:97-104.
 14. Zhong WZ, Wang Q, Mao WM, et al. Gefitinib Versus Vinorelbine Plus Cisplatin as Adjuvant Treatment for Stage II-IIIa (N1-N2) EGFR-Mutant NSCLC: Final Overall Survival Analysis of CTONG1104 Phase III Trial. *J Clin Oncol* 2021;39:713-22.
 15. Soria JC, Ohe Y, Vansteenkiste J, et al. Osimertinib in Untreated EGFR-Mutated Advanced Non-Small-Cell Lung Cancer. *N Engl J Med* 2018;378:113-25.
 16. Herbst RS, Tsuboi M, John T, et al. Osimertinib as adjuvant therapy in patients (pts) with stage IB-IIIa EGFR mutation positive (EGFRm) NSCLC after complete tumor resection: ADAURA. *J Clin Oncol* 2020;38:LBA5.
 17. Chao L, Fang W, Ma H, et al. Osimertinib as neoadjuvant treatment for resectable stage II-IIIb EGFR mutant lung adenocarcinoma (NEOS). *J Clin Oncol* 2021;39:abstr 8524.
 18. Ballard P, Yates JW, Yang Z, et al. Preclinical Comparison of Osimertinib with Other EGFR-TKIs in EGFR-Mutant NSCLC Brain Metastases Models, and Early Evidence of Clinical Brain Metastases Activity. *Clin Cancer Res* 2016;22:5130-40.
 19. Wang X, Bai YF, Zeng M. First-Line Tyrosine Kinase Inhibitor with or Without Aggressive Upfront Local Radiation Therapy in Patients with EGFRm Oligometastatic Non-Small-Cell Lung Cancer: Interim Results of a Randomized Phase III, Open-Label Clinical Trial (SINDAS) (NCT02893332). *International Journal of Radiation Oncology Biology Physics* 2020;108:E81.
 20. Bonnette P, Puyo P, Gabriel C, et al. Surgical management of non-small cell lung cancer with synchronous brain metastases. *Chest* 2001;119:1469-75.
 21. Divisi D, Barone M, Zaccagna G, et al. Surgical approach in the oligometastatic patient. *Ann Transl Med* 2018;6:94.
 22. Sudmeier L, Tian S, Higgins KA. Multidisciplinary Management of Brain Metastases from Non-Small Cell Lung Cancer in the Era of Immunotherapy. *Curr Treat Options Oncol* 2021;22:77.
 23. Mantovani C, Gastino A, Cerrato M, et al. Modern Radiation Therapy for the Management of Brain Metastases From Non-Small Cell Lung Cancer: Current Approaches and Future Directions. *Front Oncol* 2021;11:772789.
 24. Gomez DR, Blumenschein GR Jr, Lee JJ, et al. Local consolidative therapy versus maintenance therapy or observation for patients with oligometastatic non-small-cell lung cancer without progression after first-line systemic therapy: a multicentre, randomised, controlled, phase 2 study. *Lancet Oncol* 2016;17:1672-82.
 25. Iyengar P, Wardak Z, Gerber DE, et al. Consolidative Radiotherapy for Limited Metastatic Non-Small-Cell Lung Cancer: A Phase 2 Randomized Clinical Trial. *JAMA Oncol* 2018;4:e173501.
 26. Guckenberger M, Lievens Y, Bouma AB, et al. Characterisation and classification of oligometastatic disease: a European Society for Radiotherapy and Oncology and European Organisation for Research and Treatment of Cancer consensus recommendation. *Lancet Oncol* 2020;21:e18-28.
 27. Akamatsu H, Ninomiya K, Kenmotsu H, et al. The Japanese Lung Cancer Society Guideline for non-small cell lung cancer, stage IV. *Int J Clin Oncol* 2019;24:731-70.
 28. Wang XS, Bai YF, Verma V, et al. Randomized Trial of First-Line Tyrosine Kinase Inhibitor With or Without Radiotherapy for Synchronous Oligometastatic EGFR-Mutated NSCLC. *J Natl Cancer Inst* 2022. [Epub ahead of print].
 29. Brighenti M, Petrelli F, Barni S, et al. Radical treatment of oligometastatic non-small cell lung cancer: Ready for prime time? *Eur J Cancer* 2017;79:149-51.
 30. Yu HA, Suzawa K, Jordan E, et al. Concurrent Alterations in EGFR-Mutant Lung Cancers Associated with Resistance to EGFR Kinase Inhibitors and Characterization of MTOR as a Mediator of Resistance.

- Clin Cancer Res 2018;24:3108-18.
31. Gomez DR, Tang C, Zhang J, et al. Local Consolidative Therapy Vs. Maintenance Therapy or Observation for Patients With Oligometastatic Non-Small-Cell Lung Cancer: Long-Term Results of a Multi-Institutional, Phase II, Randomized Study. *J Clin Oncol* 2019;37:1558-65.
 32. Peters S, Camidge DR, Shaw AT, et al. Alectinib versus Crizotinib in Untreated ALK-Positive Non-Small-Cell Lung Cancer. *N Engl J Med* 2017;377:829-38.
 33. Shi X, Dong X, Zhai J, et al. Current Evidence of the Efficacy and Safety of Neoadjuvant EGFR-TKIs for Patients With Non-small Cell Lung Cancer. *Front Oncol* 2021;11:608608.
 34. Zhang C, Li SL, Nie Q, et al. Neoadjuvant Crizotinib in Resectable Locally Advanced Non-Small Cell Lung Cancer with ALK Rearrangement. *J Thorac Oncol* 2019;14:726-31.
 35. Tsuboi M, Weder W, Escricu C, et al. Neoadjuvant osimertinib with/without chemotherapy versus chemotherapy alone for EGFR-mutated resectable non-small-cell lung cancer: NeoADAURA. *Future Oncol* 2021;17:4045-55.
 36. Zhong WZ, Chen KN, Chen C, et al. Erlotinib Versus Gemcitabine Plus Cisplatin as Neoadjuvant Treatment of Stage IIIA-N2 EGFR-Mutant Non-Small-Cell Lung Cancer (EMERGING-CTONG 1103): A Randomized Phase II Study. *J Clin Oncol* 2019;37:2235-45.
 37. Chen YY, Yen YT, Lai WW, et al. Outcomes of salvage lung resections in advanced EGFR-mutant lung adenocarcinomas under EGFR TKIs. *Thorac Cancer* 2021;12:2655-65.
 38. Wu YL, Tsuboi M, He J, et al. Osimertinib in Resected EGFR-Mutated Non-Small-Cell Lung Cancer. *N Engl J Med* 2020;383:1711-23.
 39. Wu YL, John T, Grohe C, et al. Postoperative Chemotherapy Use and Outcomes From ADAURA: Osimertinib as Adjuvant Therapy for Resected EGFR-Mutated NSCLC. *J Thorac Oncol* 2022;17:423-33.
 40. Pignon JP, Tribodet H, Scagliotti GV, et al. Lung adjuvant cisplatin evaluation: a pooled analysis by the LACE Collaborative Group. *J Clin Oncol* 2008;26:3552-9.
 41. Patchell RA, Tibbs PA, Regine WF, et al. Postoperative radiotherapy in the treatment of single metastases to the brain: a randomized trial. *JAMA* 1998;280:1485-9.
 42. Chang EL, Wefel JS, Hess KR, et al. Neurocognition in patients with brain metastases treated with radiosurgery or radiosurgery plus whole-brain irradiation: a randomised controlled trial. *Lancet Oncol* 2009;10:1037-44.
 43. Brown PD, Ballman KV, Cerhan JH, et al. Postoperative stereotactic radiosurgery compared with whole brain radiotherapy for resected metastatic brain disease (NCCTG N107C/CEC.3): a multicentre, randomised, controlled, phase 3 trial. *Lancet Oncol* 2017;18:1049-60.
 44. Vogelbaum MA, Brown PD, Messersmith H, et al. Treatment for Brain Metastases: ASCO-SNO-ASTRO Guideline. *J Clin Oncol* 2022;40:492-516.
 45. Kocher M, Soffiatti R, Abacioglu U, et al. Adjuvant whole-brain radiotherapy versus observation after radiosurgery or surgical resection of one to three cerebral metastases: results of the EORTC 22952-26001 study. *J Clin Oncol* 2011;29:134-41.
 46. Khalifa J, Amini A, Popat S, et al. Brain Metastases from NSCLC: Radiation Therapy in the Era of Targeted Therapies. *J Thorac Oncol* 2016;11:1627-43.
 47. Kayama T, Sato S, Sakurada K, et al. Effects of Surgery With Salvage Stereotactic Radiosurgery Versus Surgery With Whole-Brain Radiation Therapy in Patients With One to Four Brain Metastases (JCOG0504): A Phase III, Noninferiority, Randomized Controlled Trial. *J Clin Oncol* 2018. [Epub ahead of print].
 48. Sun A, Hu C, Wong SJ, et al. Prophylactic Cranial Irradiation vs Observation in Patients With Locally Advanced Non-Small Cell Lung Cancer: A Long-term Update of the NRG Oncology/RTOG 0214 Phase 3 Randomized Clinical Trial. *JAMA Oncol* 2019;5:847-55.

(English Language Editor: Dianne Fitzgerald)

Cite this article as: Wu H, Ning J, Li Z, Divisi D, Rossi A, Cortellini A, Um SW, Okuma Y, Lazzari C, Luo Q, Chen T. Osimertinib as induction therapy for oligometastatic non-small cell lung cancer with EGFR mutation: a case report. *Transl Lung Cancer Res* 2022;11(4):686-696. doi: 10.21037/tlcr-22-251