


Mandibular advancement with clear aligners in the treatment of skeletal Class II. A retrospective controlled study



S. Caruso, A. Nota*, S. Caruso, M. Severino, R. Gatto, S. Meuli**, A. Mattei, S. Tecco*

Università degli Studi de L'Aquila, Clinica Odontoiatrica, L'Aquila, Italy

*Vita-Salute San Raffaele University and IRCCS San Raffaele, Milan, Italy

**Private practice, Rome, Italy

e-mail: silvia.caruso@univaq.it

DOI 10.23804/ejpd.2021.22.01.05

Abstract

Aim The current study aimed to analyse the dentoskeletal effects of the Invisalign mandibular advancement (MA) device in the treatment of skeletal Class II malocclusions.

Materials and methods Pre-treatment and post-treatment lateral skull radiographs from patients treated with MA versus TB (Twin-Block Appliance) at the Department of Orthodontics of the University of L'Aquila, Italy, were traced. Eligibility criteria included $SNB < 78^\circ$; $ANB > 4^\circ$; no previous orthodontic treatments; and vertebral maturation stage (CVM) CS3. Radiographs from patients with craniofacial anomalies, or who underwent extraction treatments, were excluded. Totally, 20 patients were examined, 10 of whom treated with MA and 10 treated with TB. All the radiographs were traced by one expert operator, blind to the groups. A preliminary method error study was performed to exclude intra-operator differences.

Results Baseline characteristics of the participants were similar between the groups. Both appliances demonstrated a reduction of SNB and ANB angle, and a decrease in overjet. TB demonstrated a higher efficacy in increasing mandibular dimensions. A significant retroinclination of the upper incisor was observed in the TB group, where a decrease of SNA angles was additionally observed. The resulting differences between the two groups could be attributed to the different design of the appliances.

Conclusions The present data show the effectiveness of both TB and MA in the management of skeletal Class II malocclusions due to mandibular retrusion. But some differences exist in the dentoalveolar effect of the two appliances. MA seems indicated in Class II cases where a control of the upper frontal teeth position is needed.

KEYWORDS Functional jaw orthopaedics; Class II malocclusion; Cephalometrics; Growing subjects; Interceptive orthodontics; Removable orthodontic appliances.

Introduction

Skeletal Class II malocclusions are caused by mandibular retrusion in about 80% of the cases, which

prompted many clinicians and researchers to study and typically use functional appliances that stimulate the growth of the mandible for the treatment of these dentoskeletal disharmonies in growing subjects [Pancherz, Zieher and Hoyer, 1997].

This is a complex clinical situation that does not only involve aesthetic problems, or teeth occlusion on sagittal plane, but it is also associated with various clinical conditions that require the attention of the clinician, such as the palatal dimension [Baldini et al., 2018], mouth breathing [Caruso et al., 2018], sleep apnoea [Marino et al., 2019; Paduano et al., 2019], atypical swallowing [Silvestrini-Biavati et al., 2013], anomalies of the visual apparatus [Alberto Baldini et al., 2018; Caruso et al., 2018], and poor oral habits [Caruso, Nota, Darvizeh et al., 2019] or signs and symptoms of temporomandibular joint (TMJ) disorder [Tecco et al., 2017; Caruso et al., 2017]. Thus, treatment of Class II malocclusion is very common in the orthodontic field.

In the 1950s, William Clark developed the Twin-Block Appliance (TB) for the treatment of Class II malocclusions, which consists of two separate plates overlapping each other, with inclined acrylic surfaces that guide the mandible forward [Clark, 1988]. Many modifications to this appliance were made, while maintaining the same mechanism [Harradine and Gale, 2000]. The use of separate plates increases patient's cooperation, as opposed to a single monobloc appliance, which involves both dental arches. Consequently, TB had a widespread distribution [Graber, 1984].

Recently a mandibular advancement device (MA) was implemented by Align Technology™ (San José, CA, USA) on clear aligners, for the treatment of skeletal Class II in growing patients (Fig. 1). Similarly to the principle applied in TB, MA is composed by two pairs of lateral inclined planes (precision wings), positioned buccally in the posterior area of aligners, which come into contact each time the patient closes his mouth determining a mandibular forward position.

To date, the scientific literature does not present studies evaluating the skeletal effects caused by the use of the MA proposed with clear aligners. Thus, the current retrospective study aimed to analyse the dentoskeletal changes resulting from treatment with MA in the treatment of skeletal Class II subjects. The null hypothesis is that there is no difference in the outcomes measurements between subjects treated with MA versus TB.

Subjects and methods

In the present retrospective study, pre- and post-treatment lateral skull radiographs from patients treated with MA versus TB at the dental clinic of the University of L'Aquila (Italy) were traced. Eligibility criteria included pre-treatment $SNB < 78$ and $ANB > 4$; no history of orthodontic treatment; and vertebral maturation stage (CVM) CS3. Radiographs from patients with craniofacial anomalies or who underwent extraction treatments, were excluded. Totally, 20 pairs of radiographs were examined, 10 of patients treated with MA (Invisalign, Align Technology, San José, CA, USA) and 10 radiographs—used as controls—from patients treated with TB appliance. All the radiographs were traced by one expert operator, blind to the groups. The sample size was determined on the basis of preliminary estimated variations of the primary outcome (ANB) between T0 and T1, showing that a minimum of 5 subjects was required in order to achieve a sample power of 95% with an alpha of 0.05. The post-hoc analysis showed an actual sample power higher than 99%.

A preliminary method error study was performed to exclude intra-operator differences; thus, eight randomly selected tracings were repeated after two weeks, and Intra-Class Correlation (ICC) coefficient was used to calculate intra-rater agreement between the two sets of measurements. Demographic data of the participants are described in Table 1. The cephalometric variables are described in Table 2.

Results

Comparison of the two treatments over time revealed a difference in the mean overjet between the two groups before treatment, as TB patients showed 7.3 ± 1.4 mm and MA patients showed 4.3 ± 1.3 mm.

Cephalometric variables are reported in Table 3.

The TB treatment resulted in statistically significant changes of the parameters SNA ($p = 0.001$), SNB ($p = 0.022$), ANB ($p < 0.001$), overjet ($p = 0.001$), and $U1 \wedge ANSPNS$ ($p = 0.005$).

	Numerosity in the whole sample (n=20)	Twin Block group	MA group	Difference
Males a	10	5	5	n.s.
Females a	10	5	5	n.s.
Age (Mean \pm DS) b	10 ± 1.03	10 ± 1.05	10 ± 1.05	n.s.

a: χ^2 test
 b Mann-Whitney test
 n.s. no statistically significant difference between groups

TABLE 1 Demographic characteristics of the participants in the two groups.

Variable	Definition
SNA (degree)	The SNA angle indicates the position of the jaw on the sagittal plane, towards the anterior base of the skull.
SNB (degree)	The SNB angle indicates the position of the jaw on the sagittal plane, towards the anterior base of the skull.
ANB (degree)	The ANB angle highlights the gap between the mandibular bone base and the maxillary bone base on the sagittal plane.
Go-Me \wedge ANSPNS (degree)	Angle between mandibular plane and the plane passing through anterior and posterior nasal spine
Ar-Go \wedge Go-Me (degree)	Gonial angle between the plane passing through Articulare and Gonion and the plane passing through Gonion and Menton.
FMA (degree)	Angle between Frankfurt plane and mandibular plane
U1 \wedge ANSPNS (degree)	Angle between the long axis of the upper central incisor and the plane passing through anterior and posterior nasal spine
L1 \wedge GoMe (degree)	Angle between the long axis of the lower central incisor and the mandibular plane

TABLE 2 Cephalometric analysis.

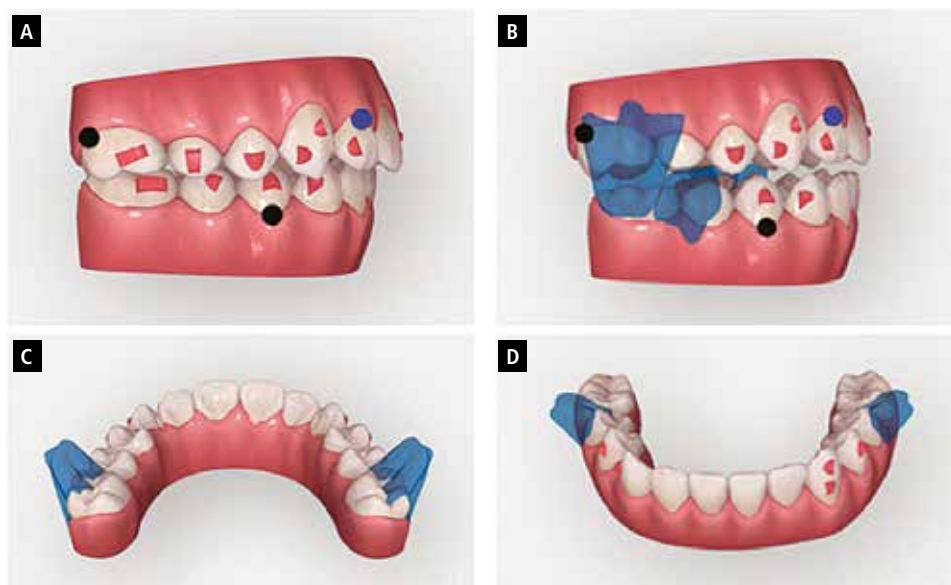


FIG. 1 The MA system for clear aligners. A: vestibular view without MA wings. B: vestibular view with MA wings. C: occlusal view of the upper dental arch. D: occlusal view of the lower dental arch.

	TB group			MA group			TB vs MA Interaction time#treatment comparison (p value)
	Mean ± SD		⊗ pre vs post p value	Mean ± SD		⊗ pre vs post p value	
	Pre	Post		Pre	Post		
SNA (°)	85.2 ± 4.87	82.2 ± 3.29	(-3) 0.001*	79.5 ±1.5	79.7 ±1.9	(0.2) 0.791	<0.001§
SNB (°)	76.7 ± 4.6	79.9 ± 1.7	(3.2) 0.022*	73.8 ±2.1	78.2 ±2.6	(4.4) 0.002*	0.340
ANB (°)	8.5 ± 3.8	2.9 ± 0.9	(-5.6) <0.001*	5.7 ±1.9	2.3 ±0.8	(-3.4) 0.002*	<0.001§
Overjet (mm)	(pre/post difference: -3.3 mm) p=0.001*			(pre/post difference: -1.4 mm) p=0.118			0.001§
Overbite (mm)	(pre/post difference: -0.1 mm) p=0.949			(pre/post difference: -3.15mm) p=0.049*			0.140
Go-Me ^ ANSPNS (°)	25.1 ±4.3	26.9 ± 4.7	(1.8) 0.370	25.3 ±4.2	26.3 ±4.4	(1) 0.610	0.580
Ar-Go ^ Go-Me (°)	123.6 ± 7.1	127.9 ± 5.3	(4.3)0.567	136.9 ±31.8	126.6 ±4.0	(-10.3)0.175	0.330
FMA (°)	24.8 ± 5.4	26.2 ± 3.4	(1.4)0.530	29.3 ± 4.9	24.4 ±5.7	(-4.9)0.030	0.080
U1 ^ ANSPNS (°)	119 ± 2.3	109 ± 9.3	(10)0.005	111.2 ±10.0	109.9 ±6.8	(1.3) 0.679	0.010§
L1 ^ GoMe (°)	93.6 ± 4.7	92.1 ±4.3	(-1.5)0.580	95.7 ±7.8	98.1 ±6.8	(2.4)0.380	0.580

* using two-way ANOVA for repeated measurements
 § p <0.05 interaction time # treatment; the significance indicates that the two treatments have a different response over time

TABLE 3 Descriptive statistic and between-groups differences.

The treatment with MA caused significant changes in SNB (p = 0.002), ANB (p = 0.002), overbite (p = 0.049) and FMA (p = 0.030).

The comparison between the two treatments over time revealed a different response for SNA (p <0.001), ANB (p <0.001), overjet (p = 0.001) and U1^ANSPNS (p = 0.010).

Discussion

The present retrospective study aimed to investigate the efficacy of two appliances for the treatment of skeletal Class II due to mandibular retrusion. In order to compare the two devices, predetermined pre- and post-treatment parameters measured on the lateral skull radiograph were compared. Both therapies allowed to improve the harmony of the face with a reduction in convexity, caused by the mandibular retrusion.

Both devices, TM and MA, are based on the same mechanism of the inclined planes that force the jaw to an advanced forced position, with subsequent neuromuscular adaptation and a new spatial position [Oda et al., 2016]. Therefore, the forced forward position of the mandible induces a series of changes, that contribute to the correction of the mandibular retrusion, and a general change in the cranio-cervical posture of Class II malocclusion [Tecco et al., 2005].

In the present sample, the SNB angle increase revealed a statistically significant mandibular advancement both with TB (from 76.7±4.6 to 79.9±1.7; p=0.022) and with MA (from 73.8±2.1 to 78.2±2.6; p=0.002), suggesting the efficacy of both devices. The results obtained with TB show the same trend of those reported in previous studies in the literature [Baysal and Uysal, 2014; Burhan and Nawaya, 2015; O'Brien et al., 2003; Nelson, Harkness and Herbison, 1993; Santamaria-Villegas et al., 2017; Tepedino et al., 2018], i.e. TB causes an increase of mandibular dimensions, through mandibular advancement, achieved by the inclination of about 70° in the upper and lower plates.

For both appliances, early detection is fundamental to intercept malocclusions timely [Grippaudo et al., 2013; Giuca et al., 2015]. The right time to start an interceptive therapy is during the peak of jaw growth, which roughly coincides with the peak of pubertal skeletal growth, when there is the maximum rate of condylar development [Nota et al., 2018; Caruso et al., 2017]. In addition, this pubertal peak also coincides with the maximum growth of the individual. In the present study, proper timing was identified by assessment of the stage of maturation of the cervical vertebrae (the CVM method), and coincides with the CS3 stage [Franchi, Baccetti and McNamara, 2000].

From our results, some differences between the two groups were observed for the maxillary position. While with MA, there was no variation of SNA angle (from 79.5±1.5 to 79.5±1.9; p = 0.791), the TB showed a significant reduction of the same parameter from 85.2±4.87 to 82.2±3.29 (p=0.001). This SNA angle reduction observed in the TB group could be associated with retroinclination of the upper incisors, which could potentially induce bone remodeling around the incisor's roots, and the A point. As seen, the U1^ANSPNS angle showed a statistically significant reduction from T0 to T1 only in the TB group. Regarding the incisors position, also Illing et al. [1998] reported a statistically significant retraction of upper incisors, and a moderate proinclination of the lower incisors (that cannot be confirmed in the present sample) as a consequence of TB treatment.

Differently, it seems that clear aligners have a biomechanical action to control the incisors inclination, that could be attributed to its structure, that surrounds the tooth crown surface, differently from functional appliances as TB. In this, clear aligners seem to overcome one of the most commonly recognised limits of Class II functional appliances, since reduction of inclination of the upper incisor determines a dental change that helps to achieve the final occlusion, reducing the potential skeletal mandibular advancement, and modifying the kinesiographic pattern of occlusion [Monaco et al., 2013].

By examining the two groups, both devices yielded a

decrease in the ANB angle, which was significantly higher ($p < 0.001$) in the TB group (from 8.5 ± 3.8 to 2.9 ± 0.9) compared with the MA group (from 5.7 ± 1.9 to 2.3 ± 0.8). This could be related to both the reduction of SNA in the TB group, and to the difference of mean ANB at T0 between the two groups. The present result seems to confirm the clinical efficacy of both devices in correcting skeletal Class II. In addition, the overjet decreased in both groups due to the mandibular advancement and, in the case of TB, the retroclination of the upper incisors. Anyway, as for the ANB angle, this could be related with the higher overjet at T0 and with the retroclination of upper incisors observed after treatment, in the TB group.

The control of the upper incisor inclination, observed in the MA group, could be crucial in cases of Class II, Division 2, where a normal overjet should be obtained in order to allow the mandible to be correctly advanced, free to express its growth potential. Another clinical application of MA could be in cases of adolescent patients with a recent condyle-disc incoordination of the TMJ, for which a treatment with anterior repositioning of the jaw proved to be more efficient than a stabilising splint to reduce joint pain and noise [Tecco et al., 2004], because in these cases the MA allows to correct teeth alignment and mandibular condyle position. In addition, MA seems useful in cases of special needs patients, for whom conventional orthopaedic appliances might not be indicated [Giuca et al., 2016].

A clinically significant control of upper incisor inclination by clear aligners has already been demonstrated in literature during upper molars distalisation [Caruso, Nota, Ehsani, et al., 2019]; this control seems clinically comparable to that obtained with the Herbst appliance with miniscrews as anchorages for incisor teeth [Manni et al., 2019], although it is known that the application of a miniscrew in a growing patient can cause problems with primary stability [Silvestrini Biavati et al., 2011]. Therefore, the advantage of the aligners in controlling the frontal group and its protrusion seems evident in these cases.

In the present sample, both appliances showed a good control of the position of the lower incisors. This finding suggests that there was no lower dentoalveolar compensation in the skeletal correction of the Class II.

Considering that the goal of the orthopaedic treatment is to maximise the skeletal effects and reduce the dental ones, it should be noted that with TB, in addition to a skeletal effect, a dental compensation was also obtained due to the retroinclination of the upper frontal group that significantly decreases the advancement potential of the jaw. On the contrary, with MA it was observed a reduced impact on the torque of the upper frontal group, and this should allow an optimisation of the skeletal effect.

Over time, the aligners have proven to be more and more versatile for orthodontic treatments. At first used mainly in the adult population, both to preserve aesthetics and to facilitate better oral hygiene [Mummolo et al., 2019] — for example in smoking patients where there is a greater risk of periodontal diseases [Giuca et al., 2014] — their use has recently spread to children, both for resolution of dental problems, such as an anterior crossbite [Meuli et al., 2018] and, with the MA device, in Class II orthopaedic-functional treatment of mandibular retrusion.

As for the vertical skeletal effects, the two appliances did not induce any significant change either in the inclination of the palatal plane to the Frankfort horizontal plane, or in

the inclination of the mandibular plane to the palatal one, as also confirmed in literature for TB [Pavoni et al., 2018]. Conversely, Illing et al. [1998] observed a small reduction in the Go-Me^{ANSPNS} with the use of the TB appliance.

The present results are limited by the small number of patients, the absence of a comparison with an untreated control group, the presence of differences in the dentoskeletal features of the two groups before orthodontic treatment and the retrospective design. For this reason, further studies with a longitudinal randomised design on a larger sample, and comparing data also with fixed functional appliances are encouraged, although, in general, the removable appliances are preferred for the patient's comfort and the better oral hygiene [Mummolo et al., 2013].

Anyway, to the authors' best knowledge, this is the first study that analyses the efficacy of clear aligners MA device.

Conclusions

The present data have demonstrated the efficacy of both TB and MA devices in the management of skeletal Class II malocclusions due to mandibular retrusion. The results show an increase in the SNB angle and a reduction in the ANB angle, between the pre- and post-treatment phase, highlighting an improvement in the sagittal relationships between the upper and lower bases. MA seems to allow a better control of the upper frontal teeth position.

References

- › Baldini A et al. Correlations between the visual apparatus and dental occlusion: a literature review. *BioMed Research International* 2018; (4): 2694517.
- › Baldini A et al. Sagittal dentoskeletal modifications associated with different activation protocols of rapid maxillary expansion. *Eur J Paediatr Dent* 2018;19(2): 151–155.
- › Baysal A, Uysal T. Dentoskeletal effects of Twin Block and Herbst appliances in patients with Class II division 1 mandibular retrognathia. *Eur J Orthod* 2014; 36(2): 164–72.
- › Burhan AS, Nawaya FR. Dentoskeletal effects of the Bite-Jumping Appliance and the Twin-Block Appliance in the treatment of skeletal Class II malocclusion: a randomized controlled trial. *Eur J Orthod* 2015; 37(3): 330–7.
- › Caruso S et al. Temporomandibular Joint Anatomy Assessed by CBCT Images. *BioMed Research International*, 2017;2916953.
- › Caruso S et al. Association of visual defects and occlusal molar class in children. *BioMed Research International* 2018; 1–4. doi: 10.1155/2018/7296289.
- › Caruso S, Nota A, Ehsani S et al. Impact of molar teeth distalization with clear aligners on occlusal vertical dimension: a retrospective study. *BMC oral health* 2019; 19(1): 182.
- › Caruso S, Nota A, Darvizeh A et al. Poor oral habits and malocclusions after usage of orthodontic pacifiers: an observational study on 3-5 years old children. *BMC Pediatrics* 2019; 19(1): 294.
- › Clark WJ. The twin block technique. A functional orthopedic appliance system. *Am J Orthod Dentofac Orthop* 1988; 93(1): 1–18.
- › Franchi L, Baccetti T, McNamara JA. Mandibular growth as related to cervical vertebral maturation and body height. *American journal of orthodontics and dentofacial orthopedics* 2000; 118(3): 335–40.
- › Giuca M et al. Levels of salivary immunoglobulins and periodontal evaluation in smoking patients. *BMC Immunology* 2014; 15(1): 5.
- › Giuca MR et al. Index of Orthodontic Treatment Need in Obese Adolescents. *Int J Dent* 2015; 2015: 876931.
- › Giuca MR et al. Craniofacial morphology in pediatric patients with Prader-Willi syndrome: a retrospective study. *Orthodontics Craniofacial Research* 2016; 19(4): 216–221.
- › Graber T. The activator: use and modifications. in Graber T, Newmann B (ed.): *Removable Orthodontic Appliances*. 2nd ed. Philadelphia: W.B. Saunders; 1984. p 198–243.
- › Grippaudo C et al. Orthodontic treatment timing in growing patients. *Eur J Paediatr Dent* 2013; 14(3): 231–6.

- › Harradine NW, Gale D. The effects of torque control spurs in twin-block appliances. *Clinical Orthodontics Research* 2000 ; 3(4): 202–9.
- › Illing HM, Morris DO, Lee RT. A prospective evaluation of Bass, Bionator and Twin Block appliances. Part I: The hard tissues. *Eur J Orthod* 1998; 20(5): 501–16.
- › Manni A et al. Herbst appliance anchored to miniscrews in the upper and lower arches vs standard Herbst: A pilot study. *Am J Orthod Dentofac Orthop* 2019; 156(5): 617–625.
- › Marino A et al. Obstructive sleep apnea severity and dental arches dimensions in children with late primary dentition: An observational study. *Cranio* 2019 Jun 25;1-6.
- › Meuli S et al. Clear aligners in pediatric age in a case of gingival recession due to malocclusion. *Dental Cadmos* 2018; 86(4).
- › Monaco A et al. Effects of correction of Class II malocclusion on the kinesiographic pattern of young adolescents: a case- control study. *Eur J Paediatr Dent* 2013; 14(2): 131–4.
- › Mummolo S et al. In-office bacteria test for a microbial monitoring during the conventional and self-ligating orthodontic treatment. *Head Face Medicine* 2013 ; 9: 7.
- › Mummolo S et al. Salivary concentrations of *Streptococcus mutans* and *Lactobacilli* during an orthodontic treatment. An observational study comparing fixed and removable orthodontic appliances. *Clin Exp Dent Res* 2020 Apr; 6(2): 181–187.
- › Nelson C, Harkness M, Herbison P. Mandibular changes during functional appliance treatment. *Am j orthod dentofac orthop* 1993; 104(2): 153–61.
- › Nota A et al. Three-dimensional volumetric analysis of mandibular condyle changes in growing subjects: A retrospective cross-sectional study. *Cranio* 2020 Sep;38(5):320-326 (Epub 2018 Oct 24).
- › O'Brien K et al. Effectiveness of early orthodontic treatment with the Twin-block appliance: a multicenter, randomized, controlled trial. Part 1: Dental and skeletal effects. *Am j orthod dentofac orthop* 2003; 124(3): 234–43. quiz 339.
- › Oda H et al. Clarifying the mechanism of effect of the Bionator for treatment of maxillary protrusion: A percentile growth study. *Eur J Paediatr Dent* 2016; 17(3): 213–219.
- › Paduano S et al. OSAS in developing age: Screening of a Southern Italy population. *Eur J Paediatr Dent* 2019; 20(4): 302–305.
- › Pancherz H, Zieber K, Hoyer B. Cephalometric characteristics of Class II division 1 and Class II division 2 malocclusions: a comparative study in children. *Angle Orthod* 1997; 67(2): 111–20.
- › Pavoni C et al. Treatment timing for functional jaw orthopaedics followed by fixed appliances: a controlled long-term study. *Eur J Orthod* 2018; 40(4): 430–436.
- › Santamaria-Villegas A et al. Effect of removable functional appliances on mandibular length in patients with class II with retrognathism: systematic review and meta-analysis. *BMC Oral Health* 2017; 17(1): 52.
- › Silvestrini-Biavati A et al. Clinical association between teeth malocclusions, wrong posture and ocular convergence disorders: an epidemiological investigation on primary school children. *BMC Pediatrics* 2013; 13: 12.
- › Silvestrini Biavati A et al. Three-dimensional tomographic mapping related to primary stability and structural miniscrew characteristics. *Orthod Craniofac Res* 2011; 14(2): 88–99.
- › Tecco S et al. Treatment of joint pain and joint noises associated with a recent TMJ internal derangement: A Comparison of an anterior repositioning splint, a full-arch maxillary stabilization splint, and an untreated control group. *Cranio* 2004; 22(3): 209–219.
- › Tecco S. et al. Evaluation of cervical spine posture after functional therapy with FR-2: A longitudinal study. *Cranio* 2005; 23(1): 53-66.
- › Tecco S et al. Temporomandibular clinical exploration in Italian adolescents. *Cranio* 2019 Mar;37(2):77-84. Epub 2017 Oct 26.
- › Tepedino M et al. Dentoskeletal effects of the bitejumping appliance and the twin-block appliance in the treatment of skeletal Class II malocclusion: A retrospective controlled clinical trial. *Oral Implantology* 2018; 11(4): 210–219.