



Acute chest pain and esophageal mucosal injury following an extreme yoga position

Case report



Ann Ital Chir, Digital Edition 2019, 8
pii: S2239253X19030573 - Epub, Sept. 30
free reading: www.annitalchir.com

Beatrice Pessia, Andrea Ciarrocchi, Splendora Marinelli, Renato Pietroletti

*General Surgery and Surgical Coloproctology, Hospital Val Vibrata, Sant'Omero (TE), University of L'Aquila, Italy

Acute chest pain and esophageal mucosal injury following an extreme yoga position. Case report

A young lady complained of the sudden onset of intense chest pain, in consequence of an extreme hyperextension of the back in a yoga position. At endoscopy a large lesion of the esophageal epithelium was detected, involving the middle third of the anterior wall of the esophagus. Other symptoms reported by the patient were dysphagia and odynophagia, depicting the typical features of intramural hematoma, also known as intramural dissection or intramural perforation of the oesophagus. The patient was managed conservatively and symptoms disappeared within a week. A barium swallow at six months reported normal findings. Different types of accidents occurring during yoga practice are reported in the literature, mainly involving musculoskeletal or nervous systems. Visceral lesions are exceptional and no similar cases have been reported in the literature.

KEYWORDS: Acute chest pain, Esophageal lesion, Intramural hematoma, Management of esophageal lesion.

Introduction

Various types of oesophageal lesions may occur for different conditions such as vomiting, intense coughing, childbirth, Valsalva manoeuvre, weight lifting. All of them involve a sudden increase of intraluminal pressure^{1,2}. Apart from the rare, complete rupture or the Mallory-Weiss tears, another kind of lesion is represented by intramural hematoma, also known as intramural dissection or intramural perforation³. Females of middle age, sometimes on anticoagulant/antiaggregant treatment, or after thrombolysis are at risk of such lesion, however sometimes occurring also spontaneously and characterized by a low severity and managed conservatively with successful outcome¹⁻⁴.

We observed a case of a young lady complaining of the typical triad of the intramural rupture of the oesophagus, namely sudden appearance of chest pain, dysphagia and odynophagia; interestingly, the onset of the symptoms was related to the achievement of an extreme yoga position.

Case report

A 19 year old woman came to our observation referred for upper G.I. endoscopy. Two days before she experienced a sudden onset of intense retrosternal pain during yoga exercise. The pain was accompanied by the feeling of a rip in the chest and shortly after by dysphagia and odynophagia. The yoga position reached by the patient is known as "the imperial pigeon" and is characterized by extreme hyperextension of the back (Fig. 1) with forced inspiration of air in the lung. The pain was intense, radiated to the neck but in a few hours became tolerable whereas dysphagia and odynophagia appeared. None of the mentioned symptoms were relieved by anti-acid assumption. For this reason the patient was referred by the GP for upper GI endoscopy.

Pervenuto in Redazione Marzo 2019. Accettato per la pubblicazione Maggio 2019

Correspondence to: Beatrice Pessia, MD, Dept. of Biotechnological and Applied Clinical Sciences, University of L'Aquila, 67010 L'Aquila, Italy (e-mail: pessiabeatrice87@gmail.com)

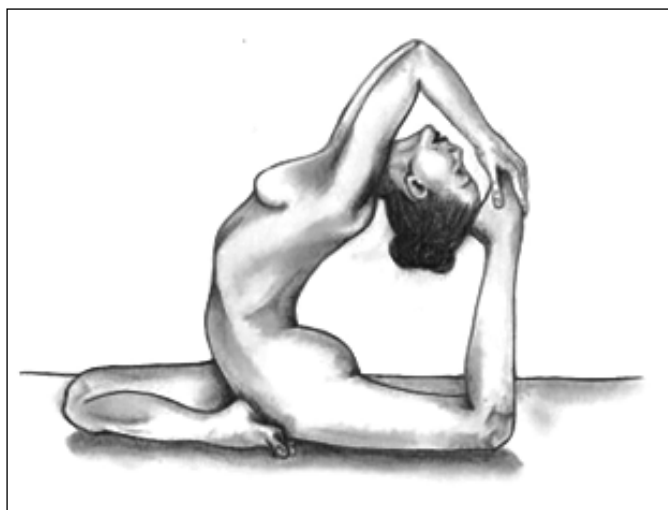

Fig 1: The yoga position so called "imperial pigeon" reached by the patient.

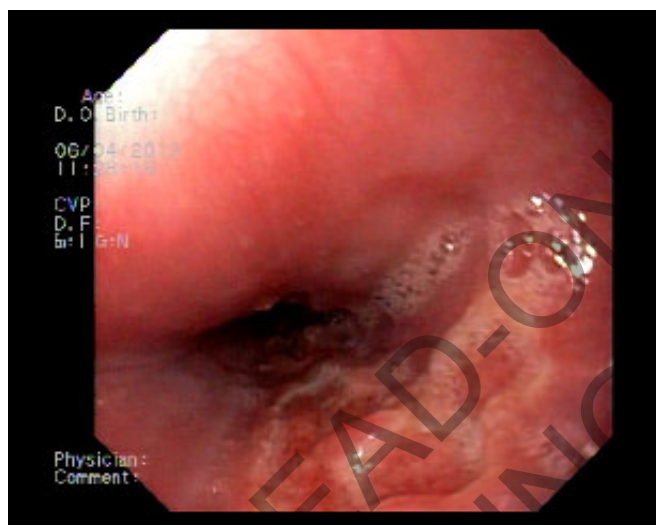


Fig 2: The large ulcer of mid oesophagus, extending down to the cardia.

The patient appeared in good general conditions, a little bit underweight with a BMI = 18. General physical examination was unremarkable; blood pressure and heart rate were normal, as well as blood screening and ECG. Upper GI endoscopy was performed using Olympus endoscope under conscious sedation with i.v. administration of 5 mg of midazolam. Pharyngeal anaesthesia was obtained with spray xylocaine.

At the level of mid oesophagus a large erosion of the epithelium was detected, occupying 1/3 of the circumference of the anterior-lateral wall. The lesion appeared with irregular shape and oedematous margins, covered with fibrin (Fig. 2) the ulcer extended downwards for about 6 cm, in proximity of the cardia. No other lesions were detected in the exploration of the stomach or duodenum.

The patient was managed conservatively (oral PPI, clear fluids by mouth) achieving symptoms remission in a week.

At six months follow up, a barium swallow showed a normal appearance of the oesophagus.

Discussion

The spectrum of oesophageal injuries ranges from Mallory-Weiss tears to acute perforation of Boerhaave's syndrome and includes the intramural hematoma. All these conditions are characterized by sex and age differences and occur mainly as a consequence of sudden intra-oesophageal pressure due to cough, vomiting, Valsalva manoeuvre, weight lifting, childbirth.

The intramural hematoma of the oesophagus is a well characterized pathological entity, affecting primarily aged woman. A predisposing factor is represented by anti-coagulant/antiaggregant use or, as recently reported, thrombolytic treatment ⁴.

The clinical triad of chest pain, dysphagia/odynophagia and haematemesis depicts the most common presentation of such patients ⁵. Hematemesis may be observed mainly at the very early stage due to temporary bleeding of the lesion and is seldom prolonged. Instead the presence of mucosal lesions (tear, ulcer) is responsible for persisting pain, severe in most instances, and dysphagia. At early stage, contrast x-ray and CT scan may show diagnostic features, whereas after 24-48 hrs, endoscopy reveals the mucosal lesion ⁶.

Our patient complained of a sudden chest pain when practicing yoga exercise; in particular, she reached an "extreme" yoga position, usually performed by experienced yoga practitioners. Such a position, known as "the imperial pigeon", implies hyperextension of the head, neck and chest, with forced inspiration (Fig. 1).

In the practice of yoga, different types of muscle-skeletal or neurological injuries may occur, just as in other kind of physical exercise or sport, however visceral organ injuries have never been described ⁷.

In the patient observed, the intense retro-sternal pain started just when she achieved the yoga position, accompanied by a feeling of a rip in the chest; two days later, the endoscopic examination detected the presence of a large oesophageal lesion in the mid oesophagus. The endoscopic picture was typical ⁸ representing most probably the remnant of an intramural hematoma, followed by mucosal dissection and subsequent sloughing of the necrotic epithelium of the oesophagus.

With respect to the aetiology, apart from the classical picture of aged woman on anti-aggregant treatment, intramural hematoma of the oesophagus has been reported in case of thrombolytic treatment ⁴ and in case of thermo ablation for atrial fibrillation ⁹. Therefore the case reported can be considered an exceptional finding since no other similar cases could be found in the literature.

In addition, our patient is the youngest of the whole world series of case reports of oesophageal intramural hematoma.

The forced inspiration made by the patient during her exercise, increasing the intraluminal pressure, could have been the main etiologic factor of the lesion, probably coupled with the extreme hyperextension of the chest. We might hypothesize that the thin body structure of the patient and the practice of yoga, both allowing a great flexibility, helped to reach such an extreme traction of the oesophagus with subsequent intramural hematoma.

Apparently there were no other predisposing factors in the patient's history such as gastro-oesophageal reflux disease, respiratory tract disease, forced vomiting etc.

Accordingly with the literature, we managed the patient conservatively with remission of the symptoms in a short time and no functional or radiologic abnormalities at follow up.

Conclusion

Since the clinical picture of intramural oesophageal hematoma can be very alarming at the start due to the intense chest pain, the main goal is to establish the correct diagnosis excluding other diseases causing of severe thoracic pain and avoiding inappropriate treatments. Good prognosis is guaranteed with the correct conservative approach.

Acknowledgements

Author are indebted to miss Debora Tramontin who kindly provided the drawing of Fig. 1.

Riassunto

Una giovane donna, dopo aver assunto una posizione di estrema iperestensione durante lo yoga, lamentava l'insorgenza improvvisa di un intenso dolore toracico. Un esame endoscopico rilevava una grande lesione dell'epi-

telio esofageo, che coinvolgeva il terzo medio della parete anteriore dell'esofago, giungendo in prossimità del cardias. Altri sintomi segnalati dalla paziente erano disfagia e odinofagia, raffiguranti le caratteristiche tipiche dell'ematoma intramurale, noto anche come dissezione intramurale dell'esofago. La paziente è stata gestita in modo conservativo e i sintomi sono scomparsi entro una settimana. Una Rx esofageo con bario a sei mesi ha riportato risultati normali.

In letteratura sono stati riportati diversi tipi di incidenti che si verificano durante la pratica dello yoga, coinvolgendo principalmente i sistemi muscoloscheletrico o nevosi. Le lesioni viscerali sono eccezionali e non sono stati riportati casi simili in letteratura.

References

1. Kerr WF: *Spontaneous intramural rupture and intramural hematoma of the oesophagus*. Thorax, 1980; 35:890-97.
2. Hill N, Zagal I, Hadas-Halper I.: *Spontaneous intramural hematoma of the esophagus*. Am J Gastroenterol, 1999; 94:2282-284.
3. Joeng ES, Kim MJ, Yoo JH, Kim DHJung JS, Koo NH, Chang SH: *Intramural hematoma of the esophagus after endoscopic pinch biopsy*. Clin Endosc, 2012; 45:417-20.
4. Silva MJ, Sajote J, Salvado V, Nunes AP, Duarte P: *Intramural hematoma of the esophagus after thrombolysis for ischemic stroke*. Am J Emerg Med, 2015; 33(3):481.
5. Cummins E, Meenal S, Eastin T, Adkin E: *A rare cause for acute chest pain in the emergency settings that is hard to swallow*. Case Rep Emerg Med, 2013; 2013:646342.
6. Hsu CC, Changchien CS: *Endoscopic and radiological features of intramural esophageal dissection*. Endoscopy, 2001; 3314:37981.
7. Holton MK, Barry AE: *Do side effects/injuries from yoga practice result in discontinued use? Results of a national survey*. Int J Yoga, 2014; 7(2):152-54.
8. Disney BR, Preece SA, Ishaq S: *Intramural esophageal hematoma: A rare cause of acute chest pain*. Endoscopy, 2014; 46 suppl1 UCTN: E607-8
9. Kim MY, Ng FS, Ariff B, Hanna GB, Whinnett Z, Kanagaratnam P, Tanner M, Lim PB: *Extensive intramural esophageal hematoma after trans-esophageal echocardiography during atrial fibrillation ablation*. Circulation, 2015; 1132(19):1847-849.